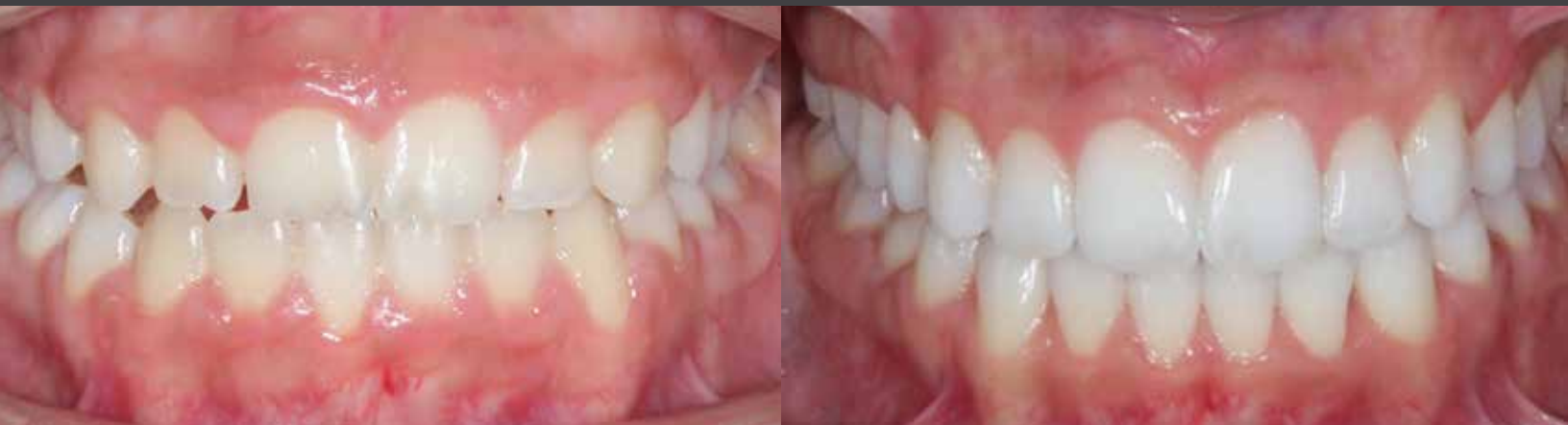



CLINICAL BOOK



CREATING CLINICAL SUCCESS

These cases are presented to show you some of our newer protocols with H4 brackets and Pitts Broad Archwires. These cases are not to be reproduced in any form.

They were submitted by “my” team of orthodontists who have mastered our protocols, making non-extraction treatment very quick and easy (using case management of “Active Early”). They all teach on my team.

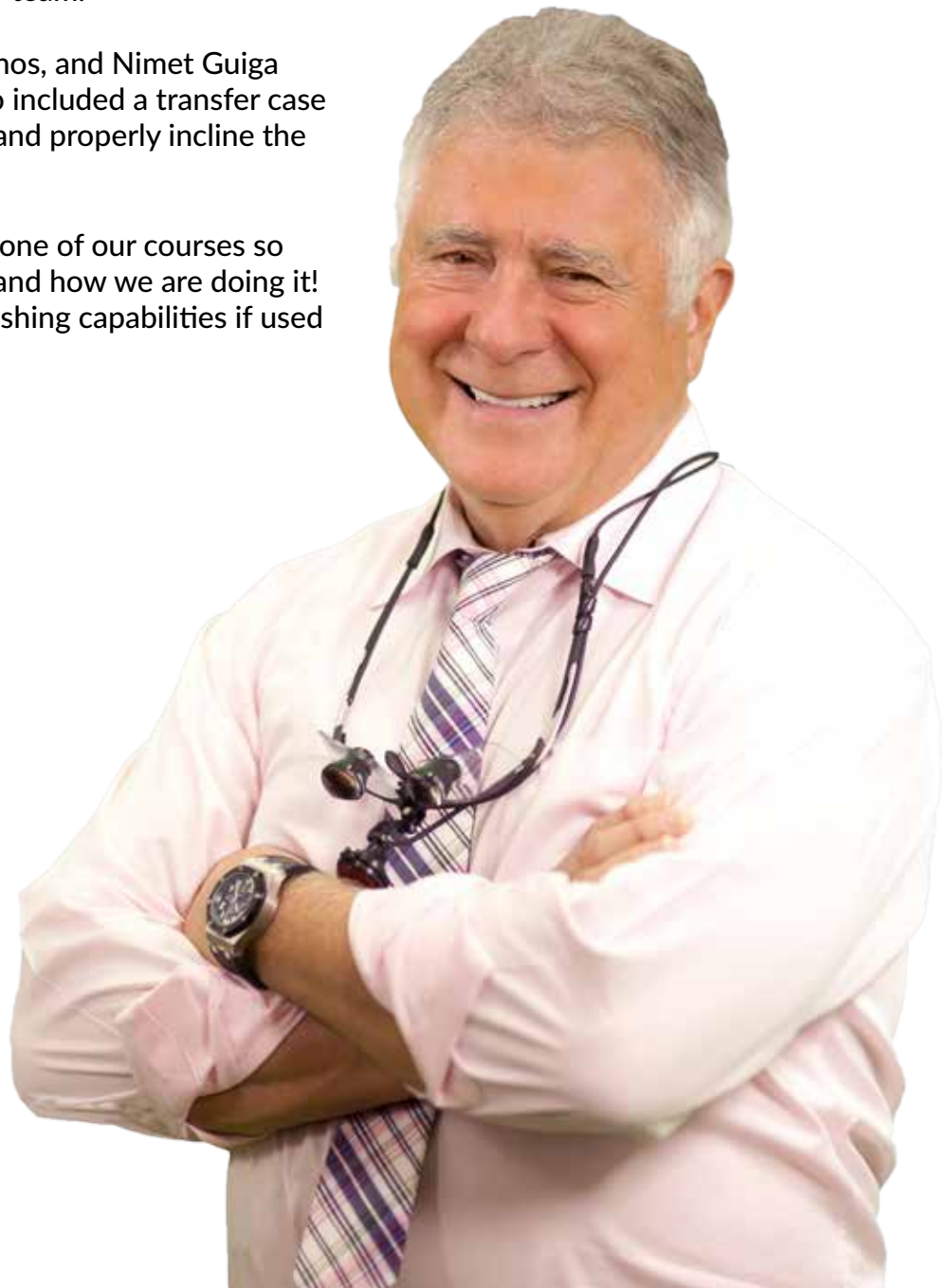
Drs. Duncan Brown, Tomas Castellanos, and Nimet Guiga have all submitted cases. I have also included a transfer case that I rebonded to create Smile Arc and properly incline the proclined incisors.

We would welcome you to come to one of our courses so we can show you what we’re doing and how we are doing it! This new bracket is superb in it’s finishing capabilities if used properly.

All the best,

A handwritten signature in black ink, appearing to read 'Tom Pitts', with a long horizontal flourish extending to the left.

Tom Pitts D.D.S., M.S.D.



CONTRIBUTORS



Dr. Thomas Pitts D.D.S., M.S.D.

Ortho Country Orthodontics

Dr. Pitts is a world renowned lecturer and clinician. He is highly recognized for his continued teaching of orthodontic finishing and clinical excellence. Dr. Pitts is an associate clinical professor at the University of the Pacific and founder of the well-respected Pitts Progressive Study Club.

Dr. Pitts has been published in multiple journals and clinical publications. He has been actively teaching the orthodontic community in a variety of settings both nationally and internationally since 1986.



Dr. Duncan Brown B.Sc., D.D.S., D. Ortho

Smile Zone Orthodontics

Dr. Duncan Brown is a highly regarded international speaker and educator in passive ligation bracket systems. Dr. Brown teaches regularly at the University of Alberta and University of Manitoba and is also a Kodak/Carestream Dental speaker and consultant.

Dr. Brown has made large contributions to the orthodontic community from creating effective hygiene programs for patients, to the G&H Pre-Torqued Archwire series and much more!



Dr. Nimet Guiga D.D.S., M.Sc.

Guiga Orthodontics

Dr. Nimet Guiga is a Portuguese-Canadian with a worldwide living and studying experience.

In addition to her authenticity, Dr. Guiga's highly specialized training and clinical experience enables her to diagnose and treat quickly and effectively even the most complex orthodontic situations. She has patients from all around the world who especially come to Cascais to seek her for orthodontic treatment.



Dr. Tomas Castellanos Arteaga D.D.S., M.Sc.D.

Tomas Castellanos Orthodontics

Dr. Tomas Castellanos is an international speaker and certified educator. Dr. Castellanos has been the coordinator of research with important works, which have developed new orthodontic and surgical techniques, that speed up the treatment time and provide striking functional and aesthetic results. He has his professional practice as an orthodontist in Colombia.

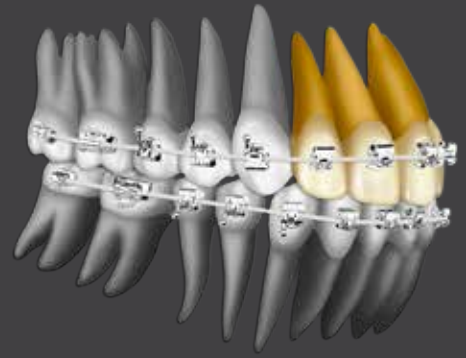
His progressive treatment planning and focus on facial aesthetics has created a highly successful name for himself early in his career.



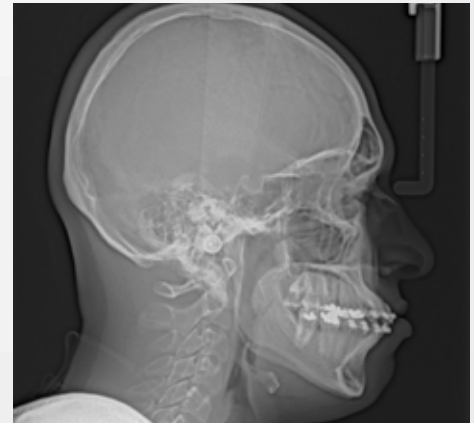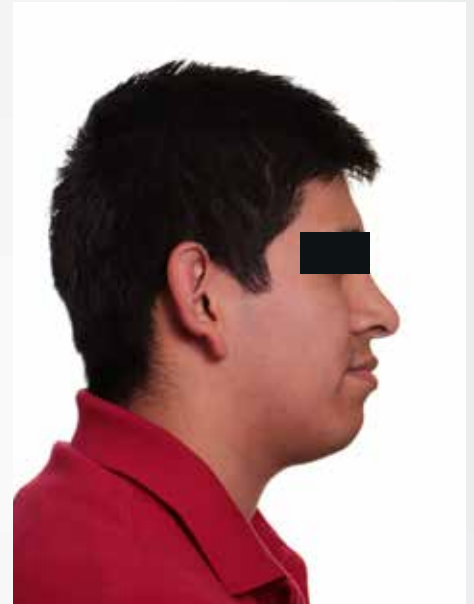Patient of
Dr. Tom Pitts

“Flipped” Appliance

*Proclination of Upper Incisors
Flat Smile Arc
Mild Crowding in the Upper Arch
Class I Bi-Maxillary Protrusion*

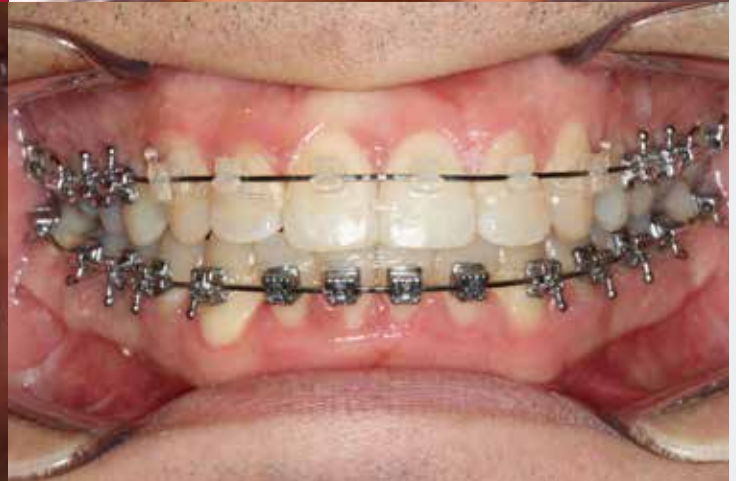
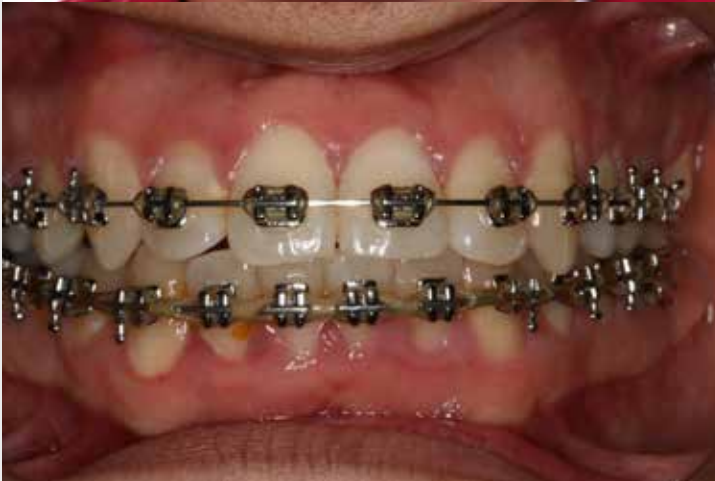
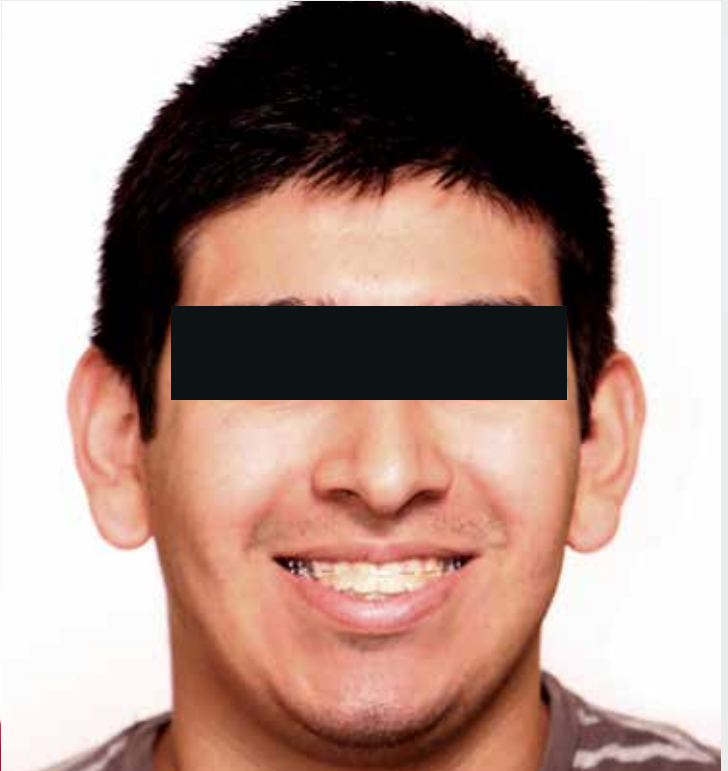INITIAL



Transfer Case - 5.5 years into treatment prior to transfer

Re-bracketed with H4 by Dr. Tom Pitts for Smile Arc and proper articulation



Initial

Re-Bonded with H4 and H4 GO

Progress 11 Weeks

Upper Anterior Brackets Flipped

Initial .018 x .018 TA AW

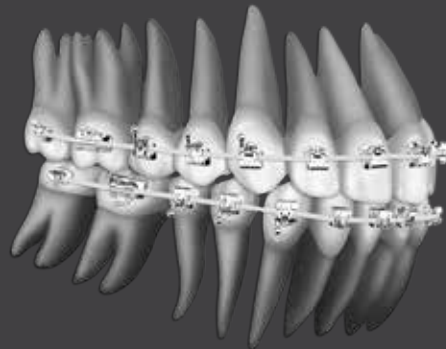
Progressed to .020 x .020 TA AW



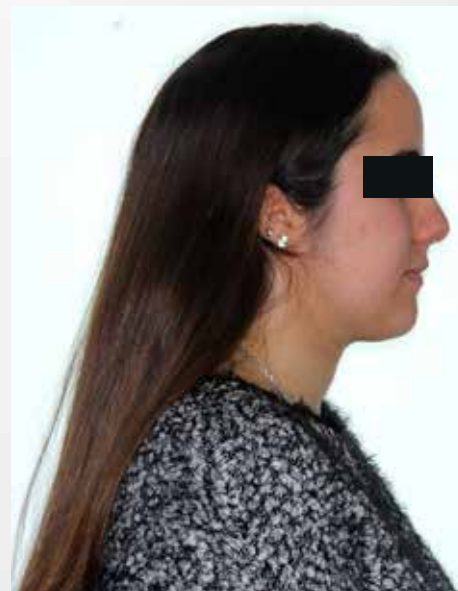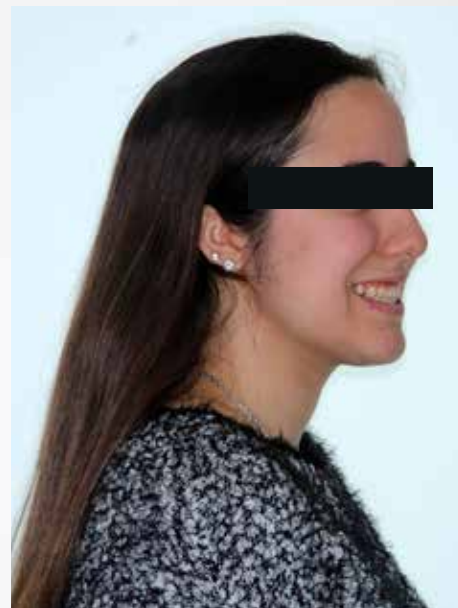Patient of
Dr. Nimet Guiga

Standard Appliance

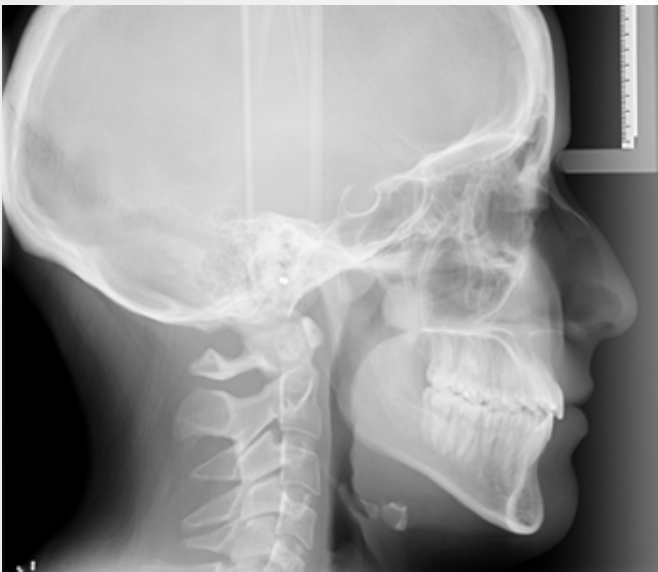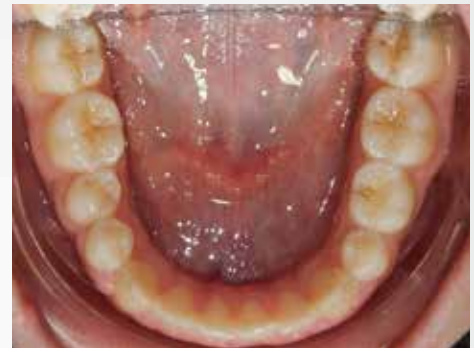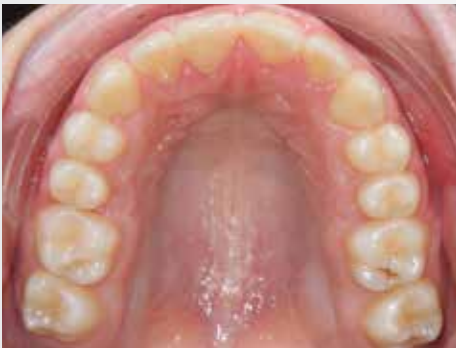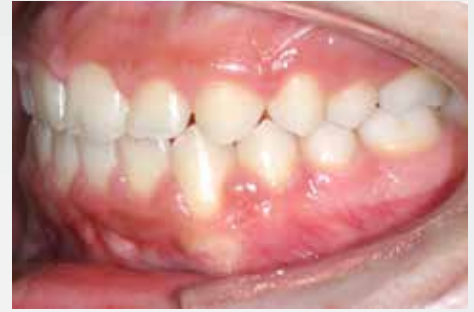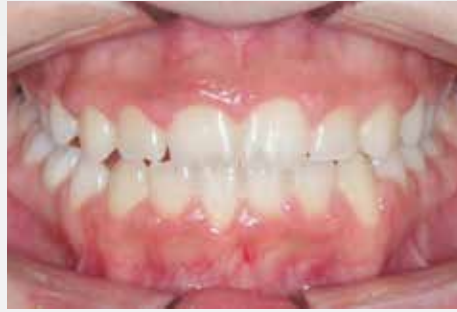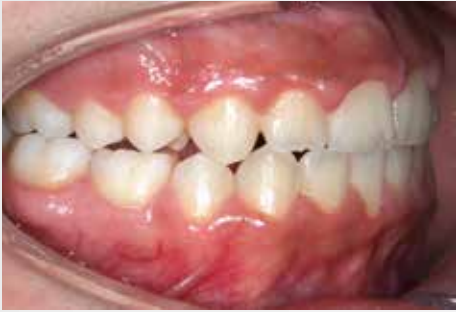- No proclination*
- No crowding in the upper arch*
- Use of class II mechanics*
- Flat Smile Arc*
- Very Short Upper Incisors*



INITIAL



Pre-Treatment Views



History

Had 6 years of prior orthodontic treatment, but was still unhappy with her smile. Dr. Guiga built up her teeth with flowable resin and lasered her gums in order to have a proper contour. Then the patient was bonding with Pitts SAP protocol. After treatment, patient was “perfected” with bioesthetics to achieve the ultimate WOW smile.

Diagnosis

Skeletal

Class I Skeletal
High Angle

Dental

Class III dental on right & I on left
Agenesis of LR5
Cross bite on right
Open bite tendency

Functional

Tongue thruster

Facial

Macroesthetics
Retrusive lips

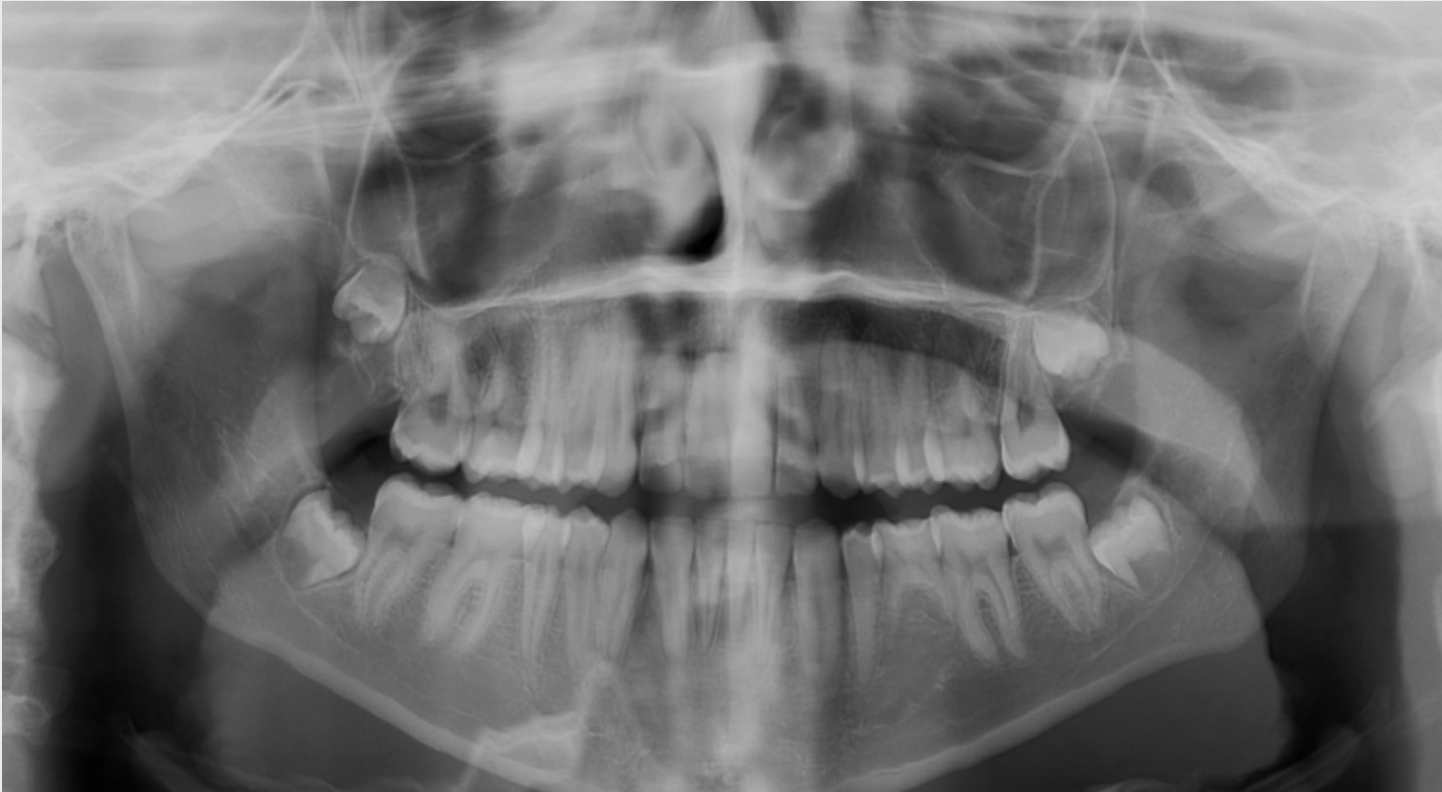Miniesthetics

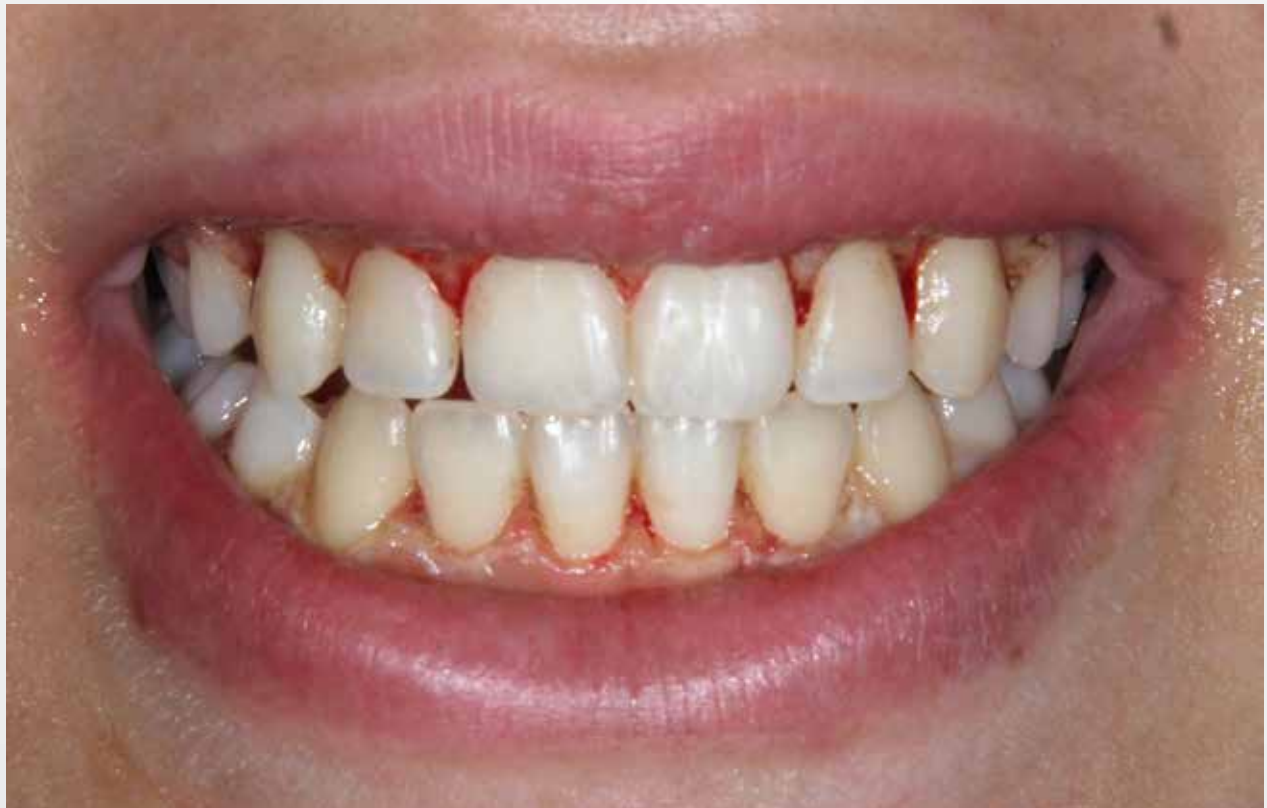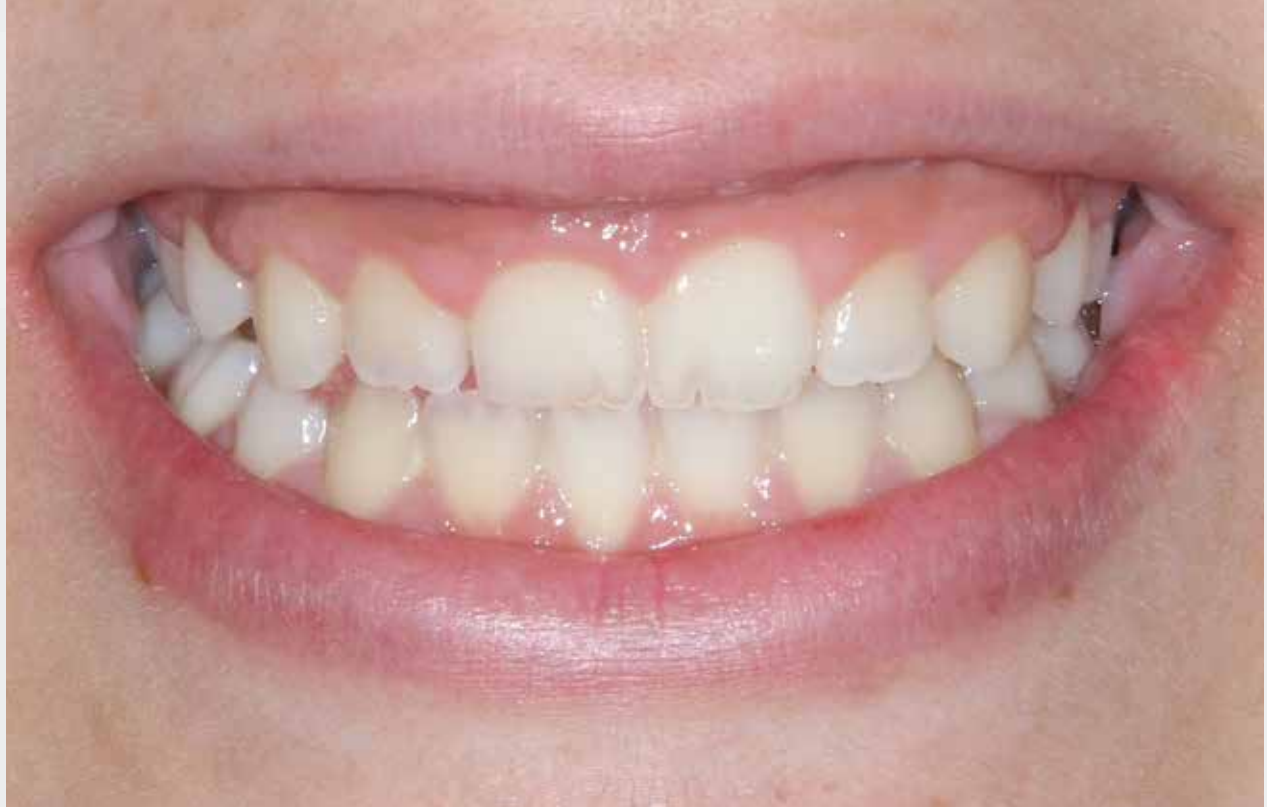Insufficient lip support
Gummy smile
Flat smile arc

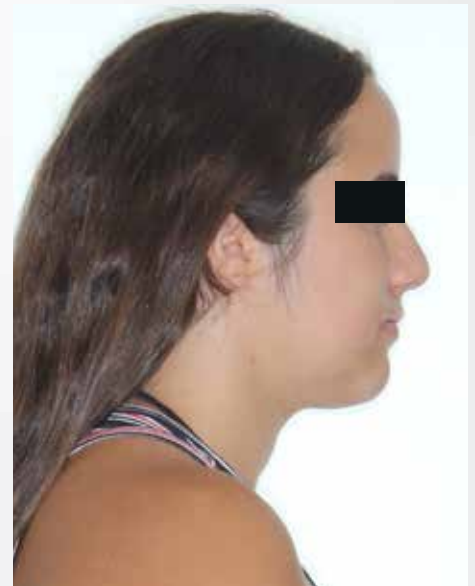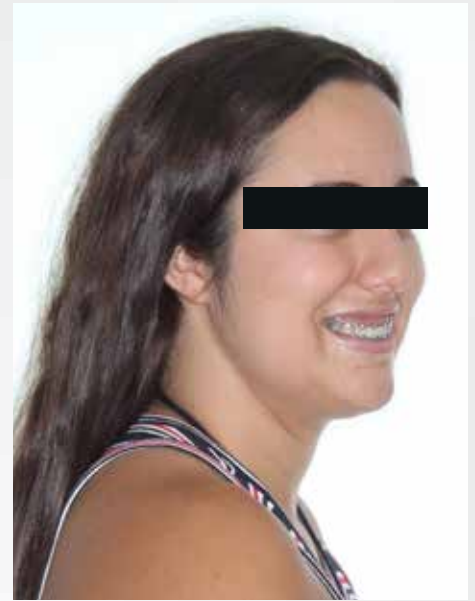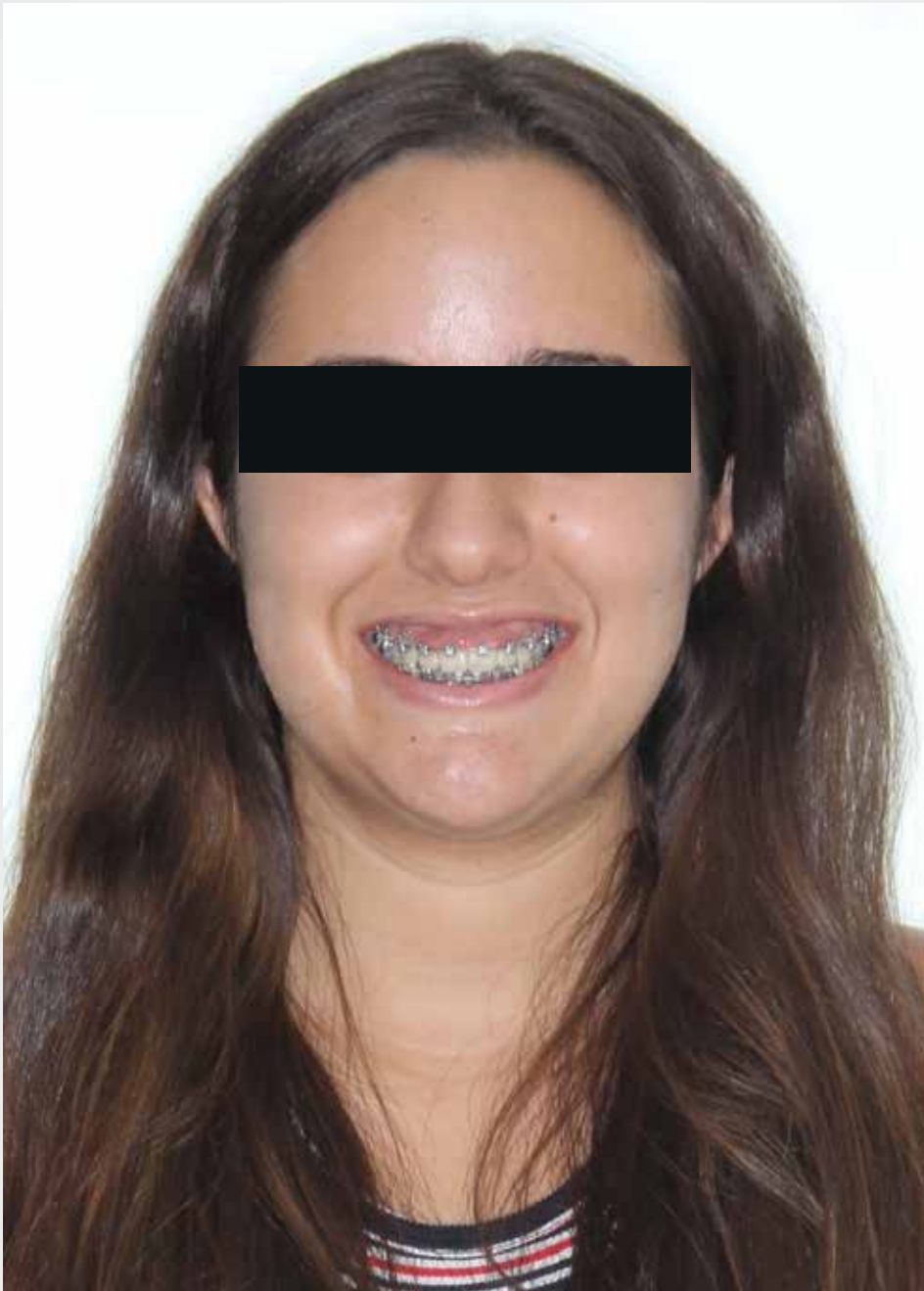Microesthetics

Lack of proportionality and form
in both pink and white tissues

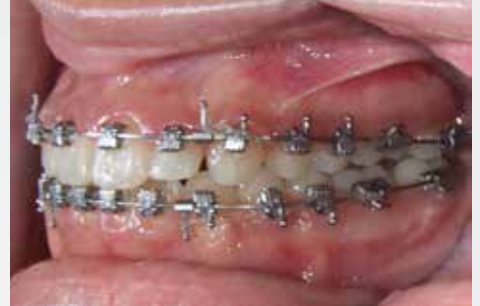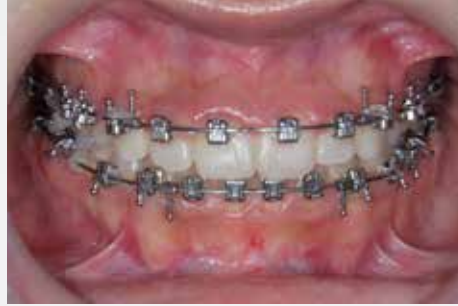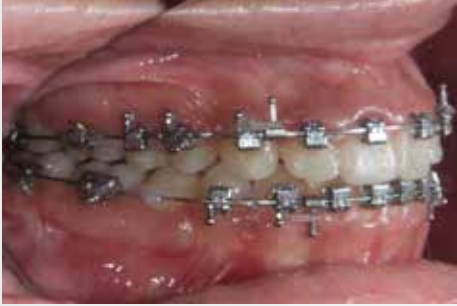Pre-Treatment Views



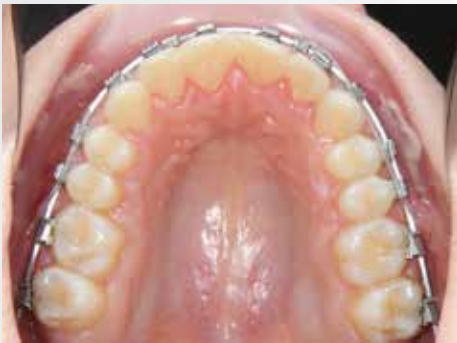



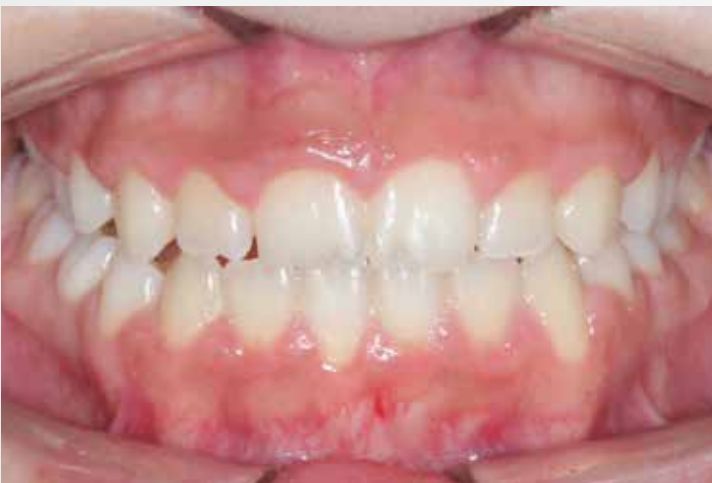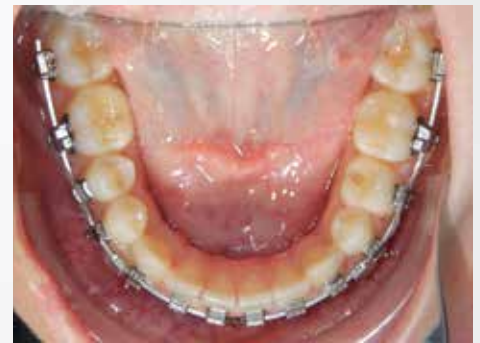In Treatment Views - 3 Months - 2 Appointments



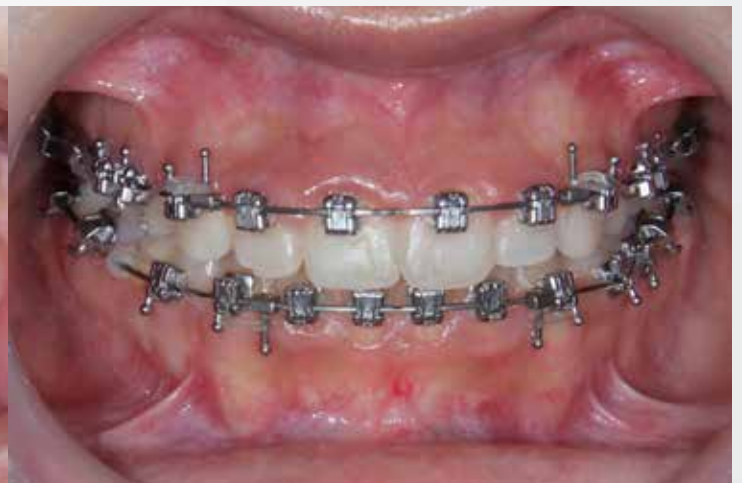In Treatment Views - 3 Months - 2 Appointments



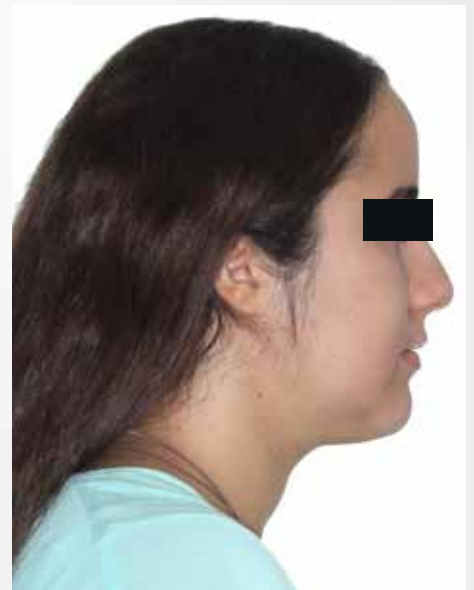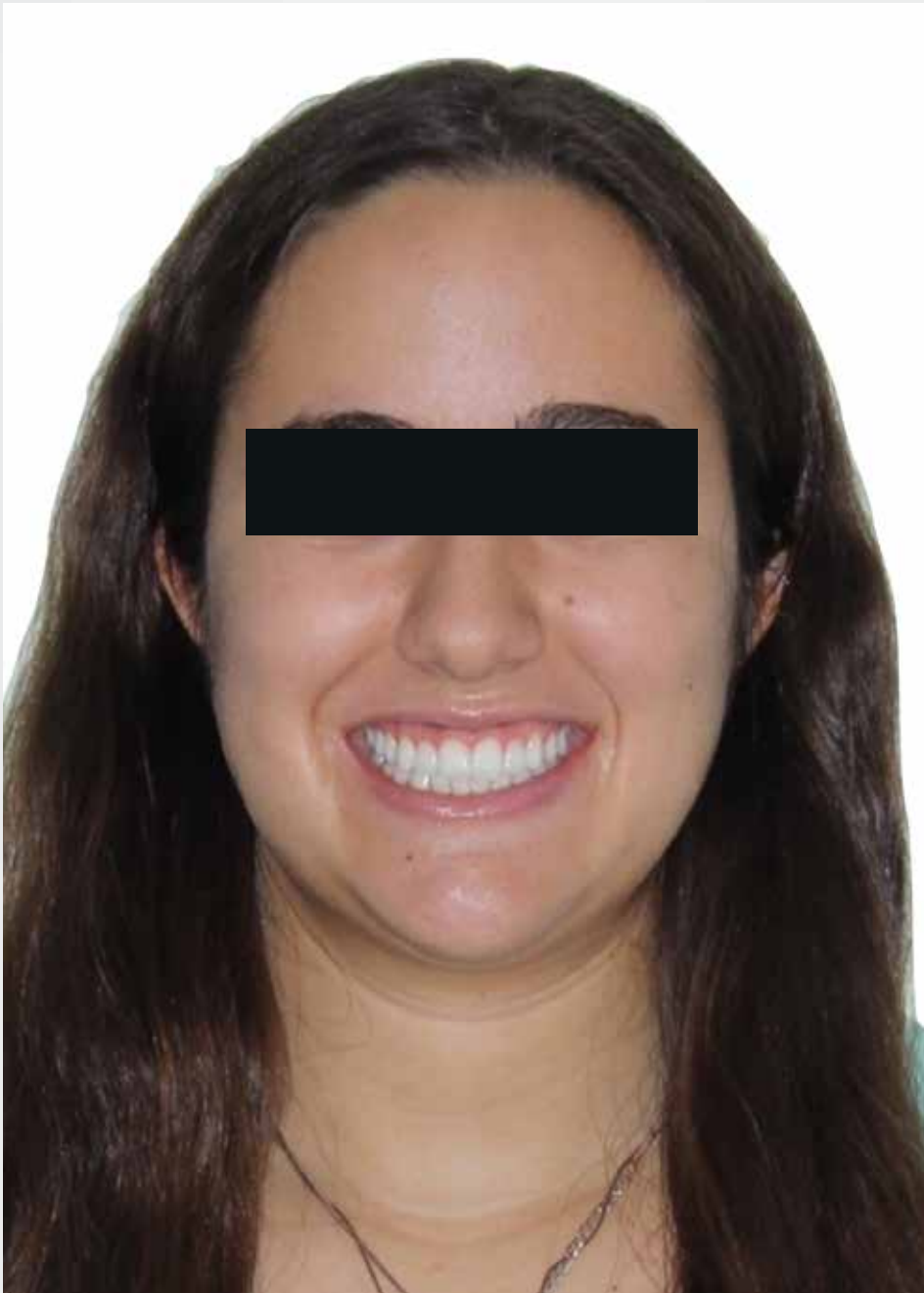Upper .019x.025 Pitts Broad
Thermal Activated
Lower .017x.025 Pitts Broad
Thermal Activated



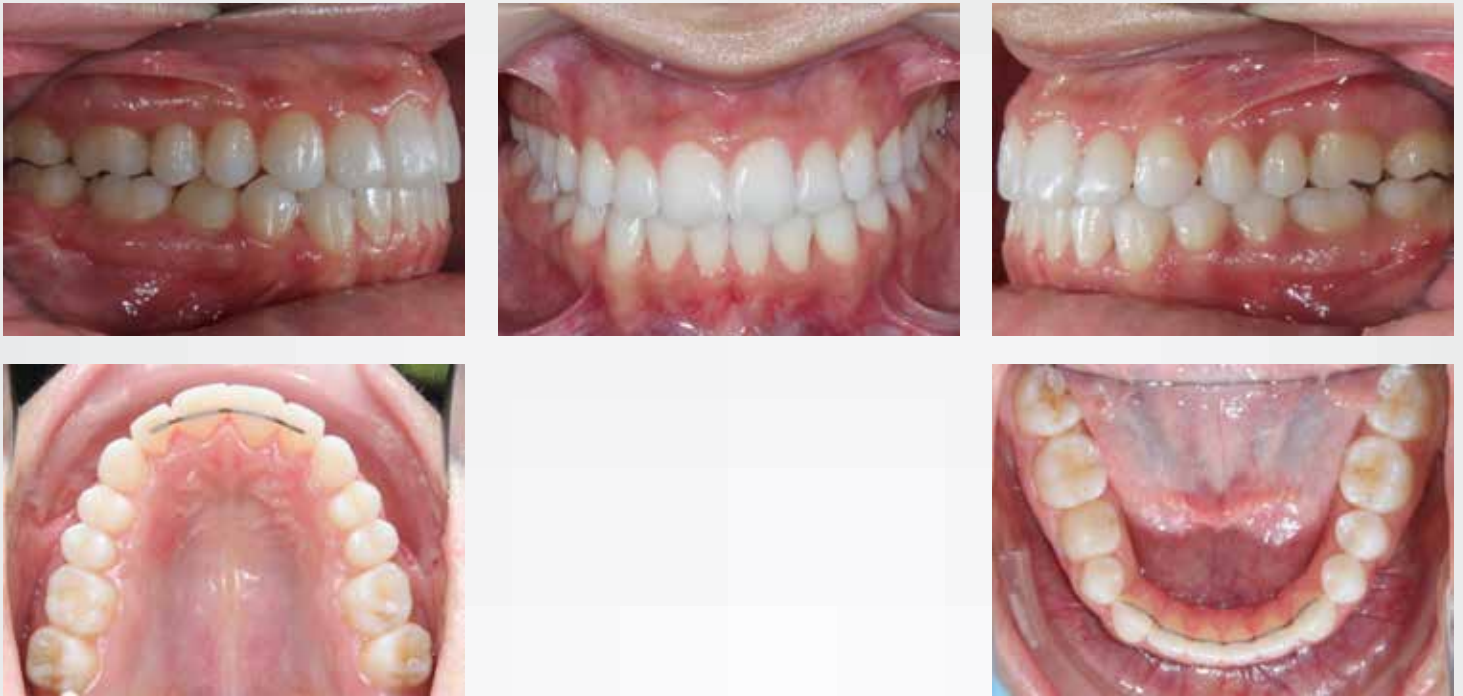
Initial



In Treatment

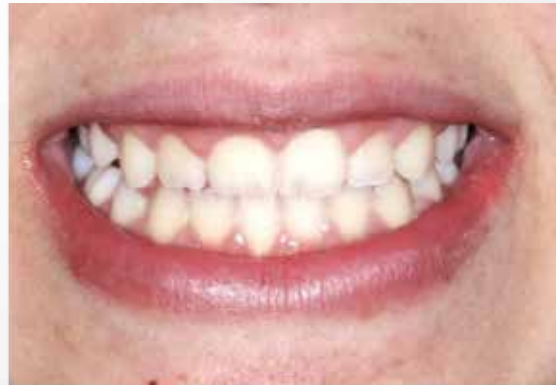
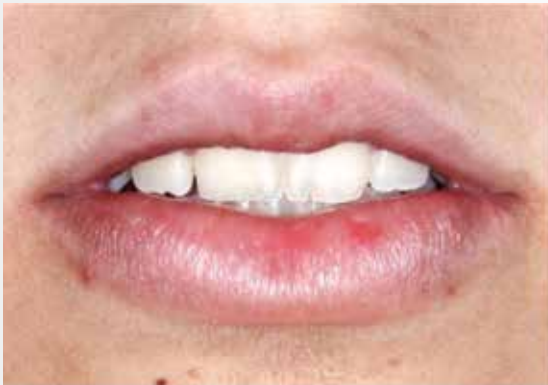
Final Treatment - 16 Months - 8 Appointments

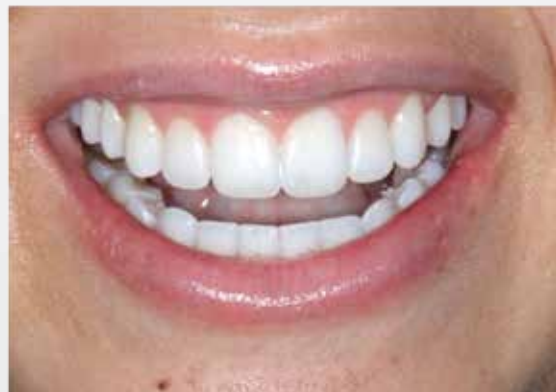
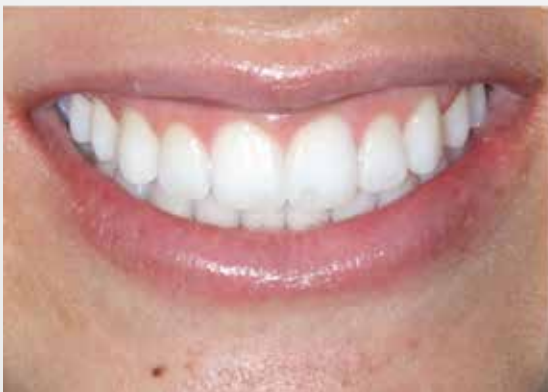
Final Treatment - 16 Months - 8 Appointments

Initial

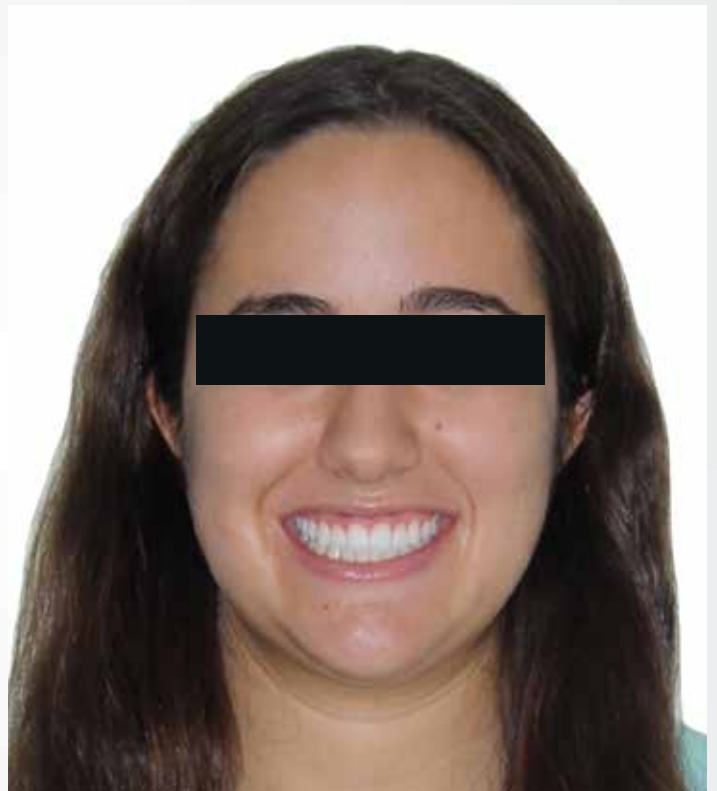

Final





INITIAL

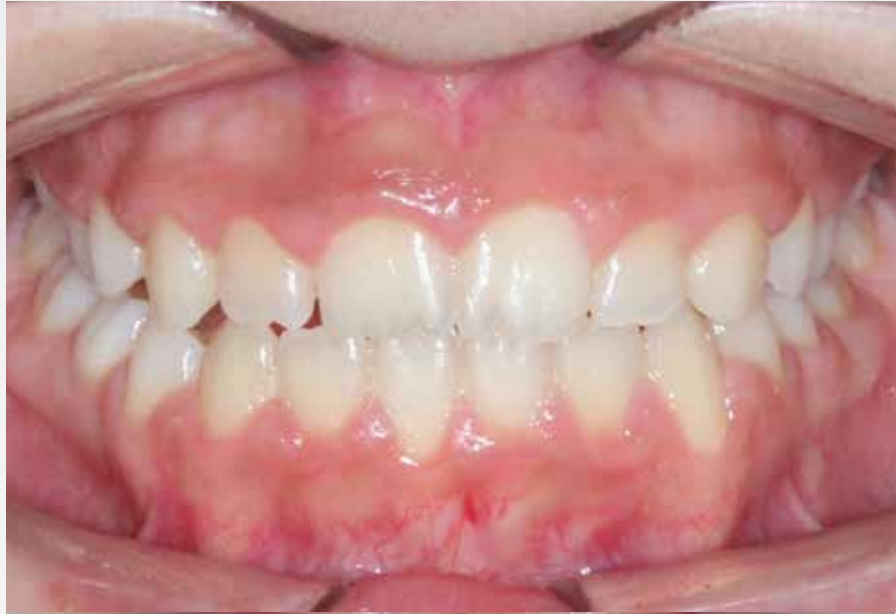

FINAL

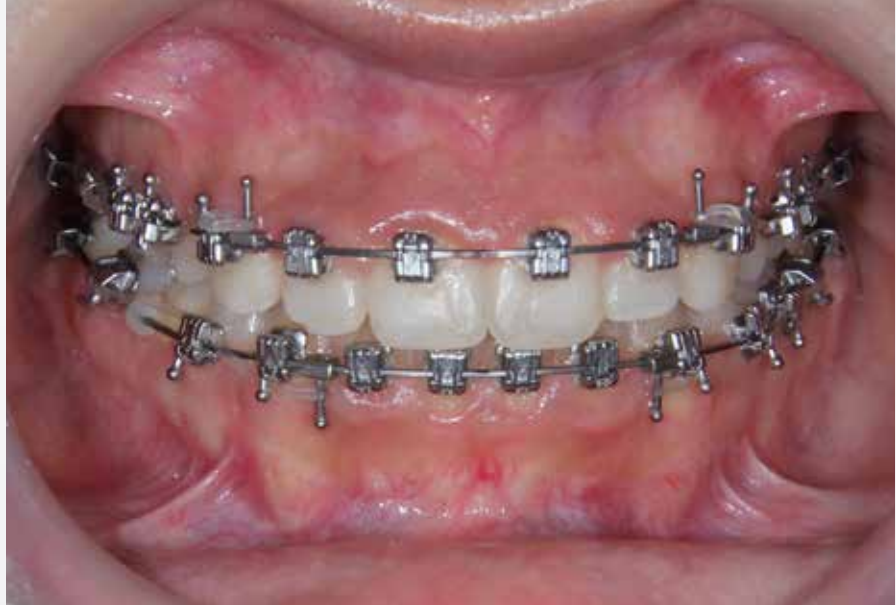

PROGRESS

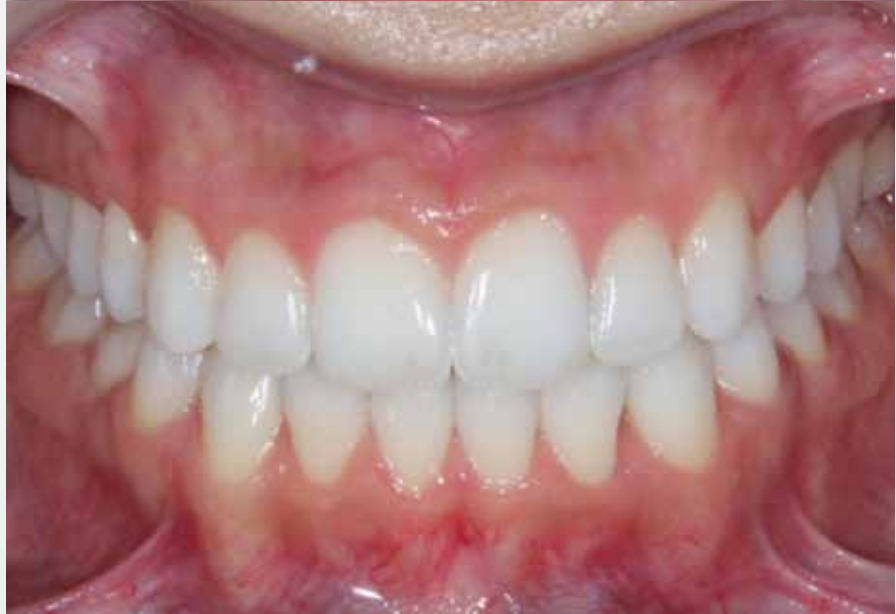INITIAL



PROGRESS



FINAL

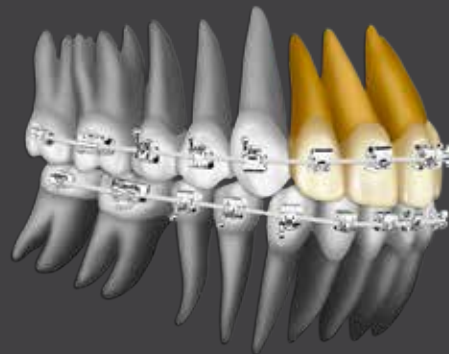




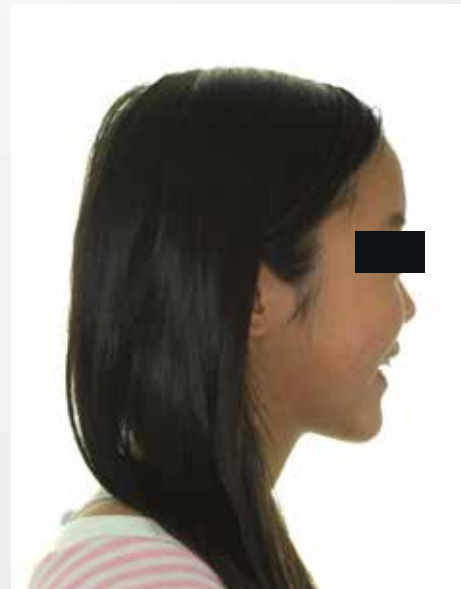
Patient of
Dr. Duncan Brown

“Flipped” Appliance

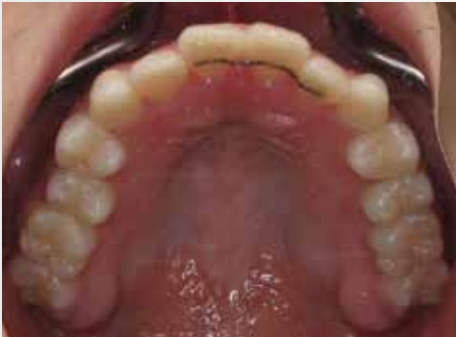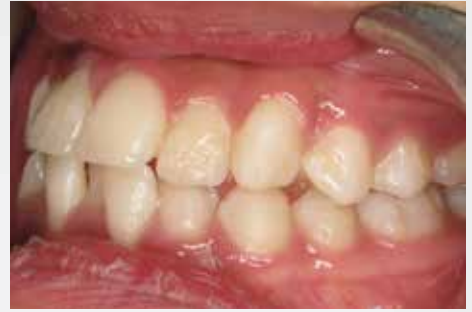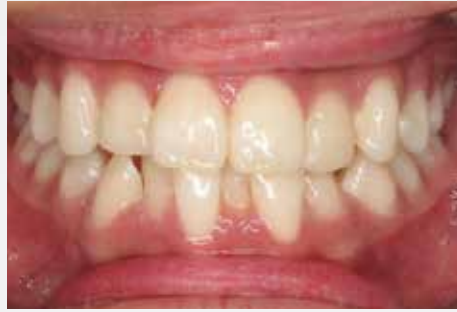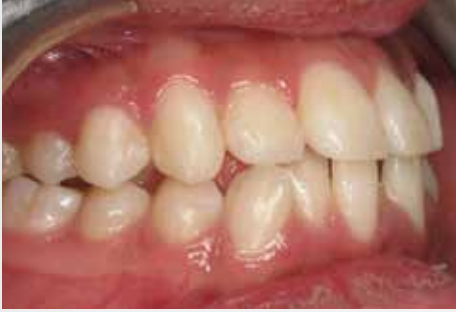*Proclination of Upper Incisors
Crowding in Lower Arch
Mild Crowding in the Upper Arch
Class III Skeletal*



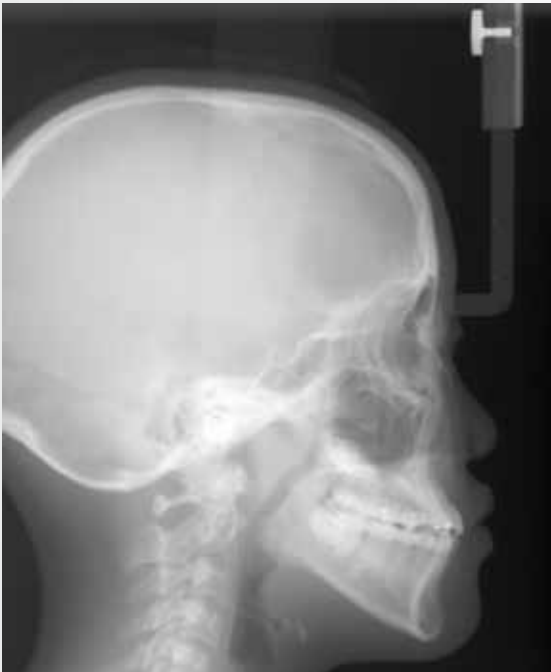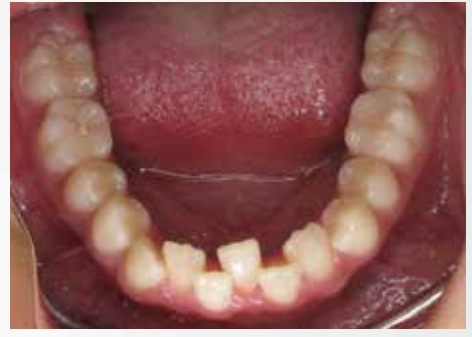INITIAL



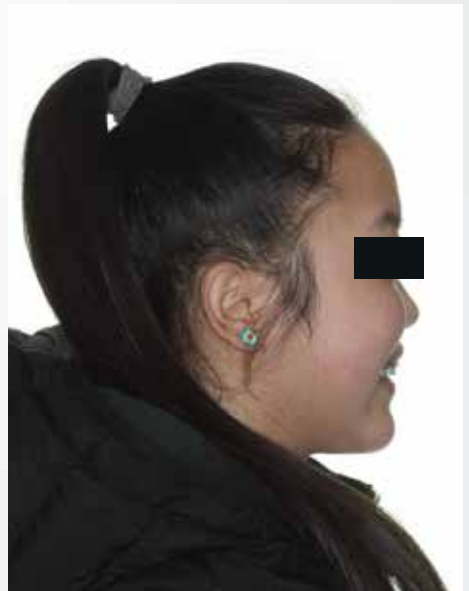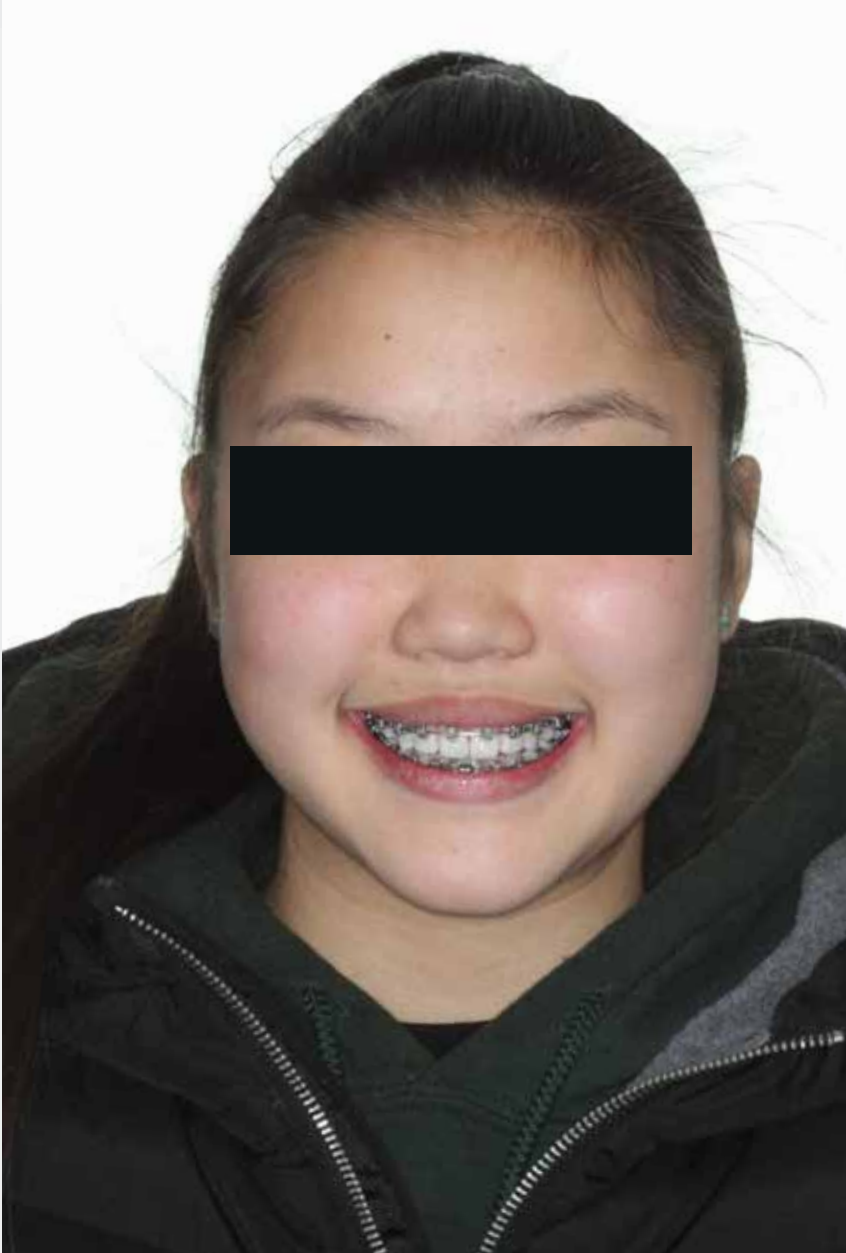Pre-Treatment Views



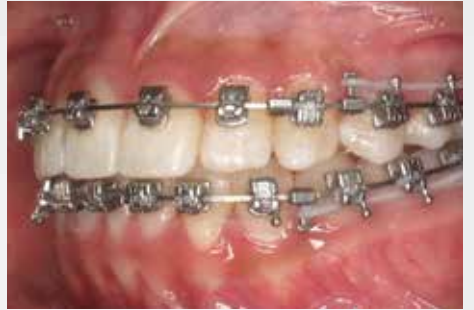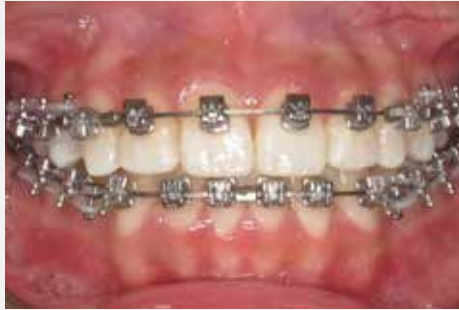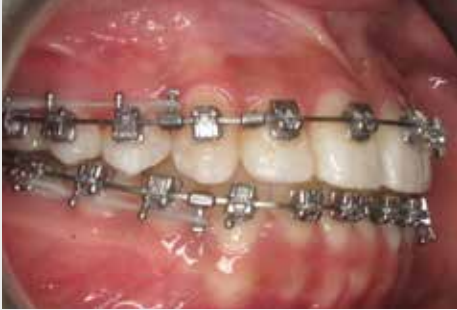Class III
Open Bite Tendency
Significant Lower Arch
Crowding
Proclined Upper Anteriors



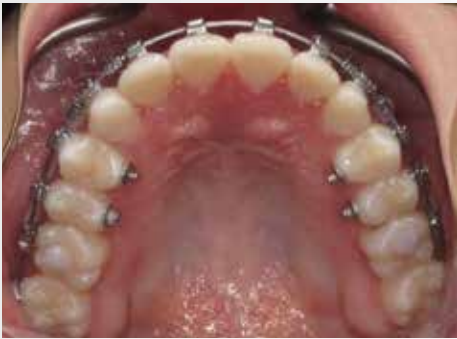Pre-Treatment Views



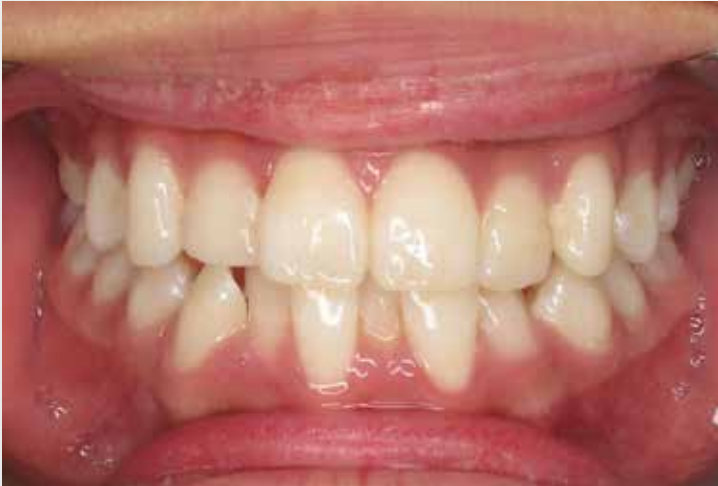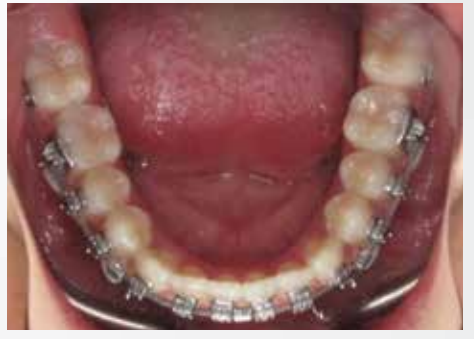In Treatment Views - 13 Months - 7 Appointments



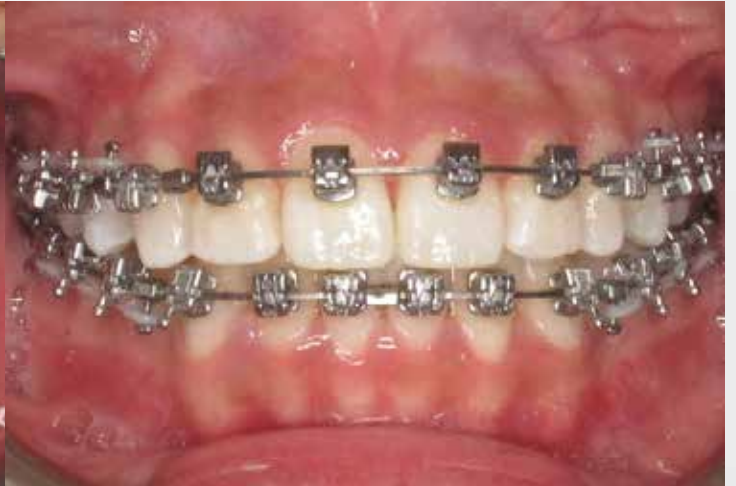In Treatment Views - 13 Months - 7 Appointments



.020 x .020 TA Upper
.014 x .025 TA Lower
TTB short Class III Elastics
2 oz PM

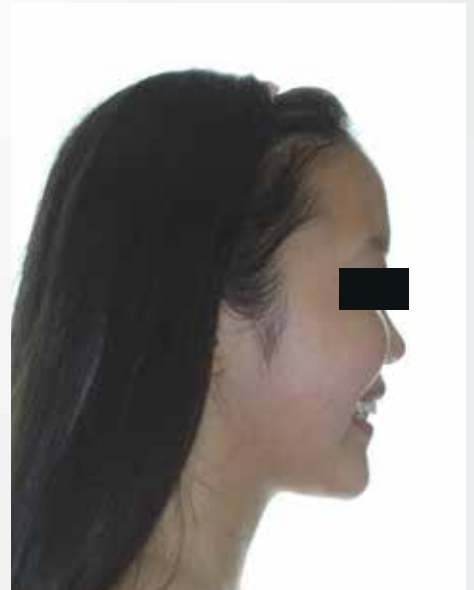
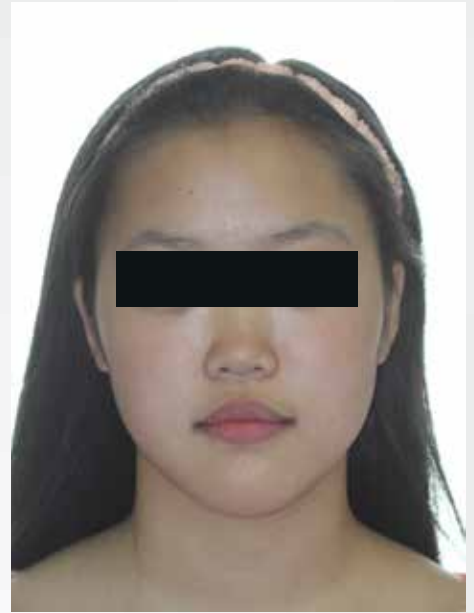
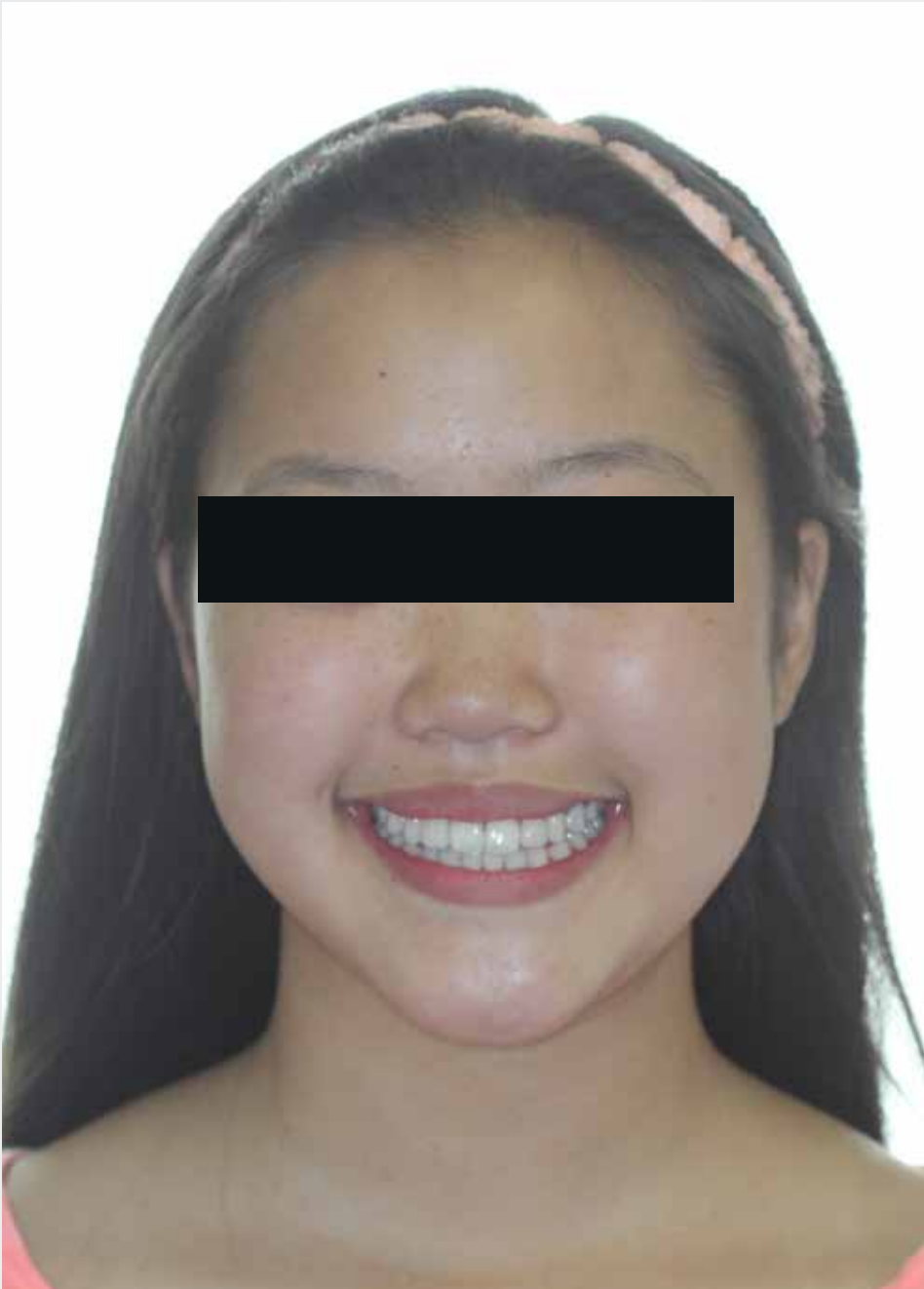Initial

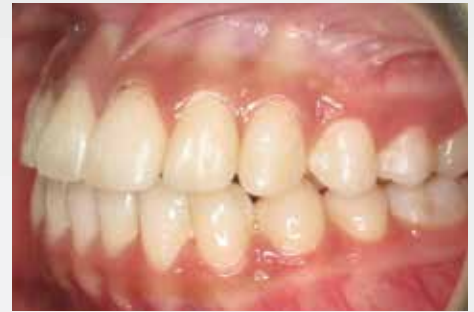
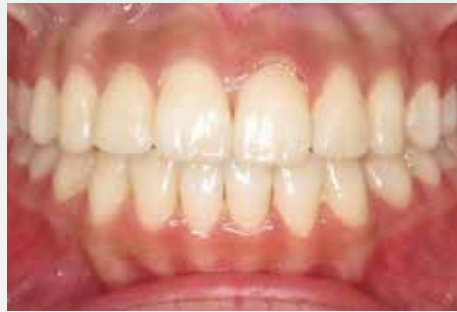
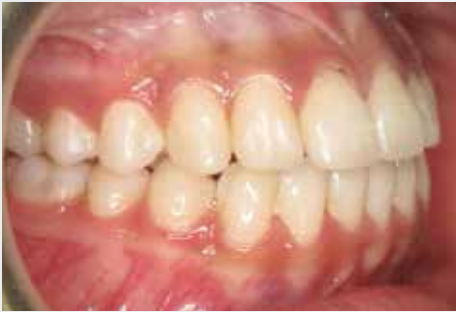In Treatment

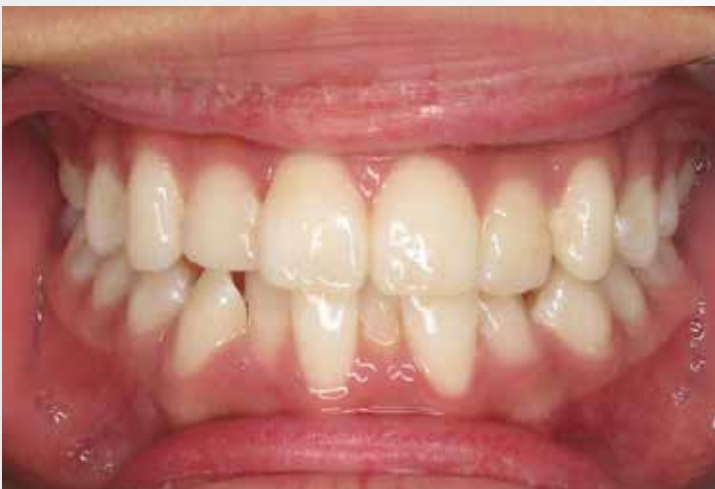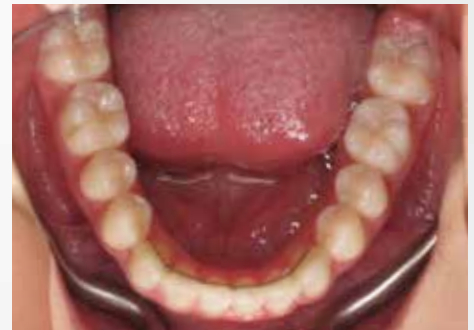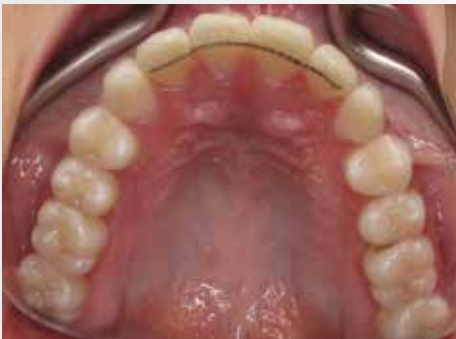© ORTHOEVOLVE 2015



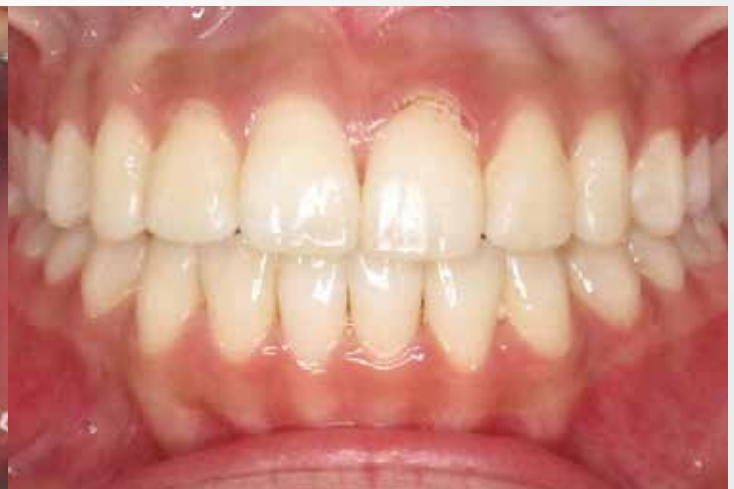Final Treatment - 18 Months - 11 Appointments



Final Treatment - 18 Months - 11 Appointments



Initial

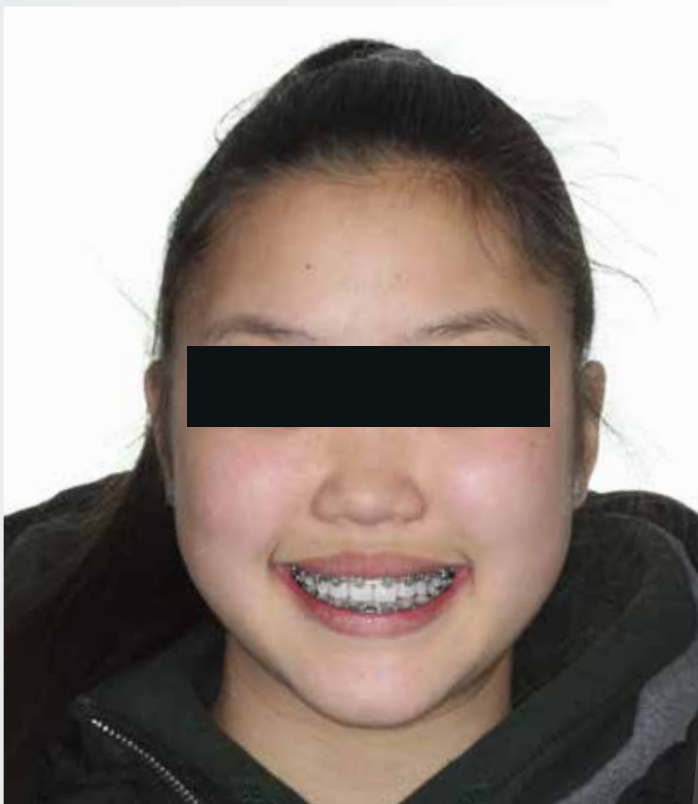

Final

Note: Final midline is slightly off due to patient consistently sleeping on left side.



INITIAL

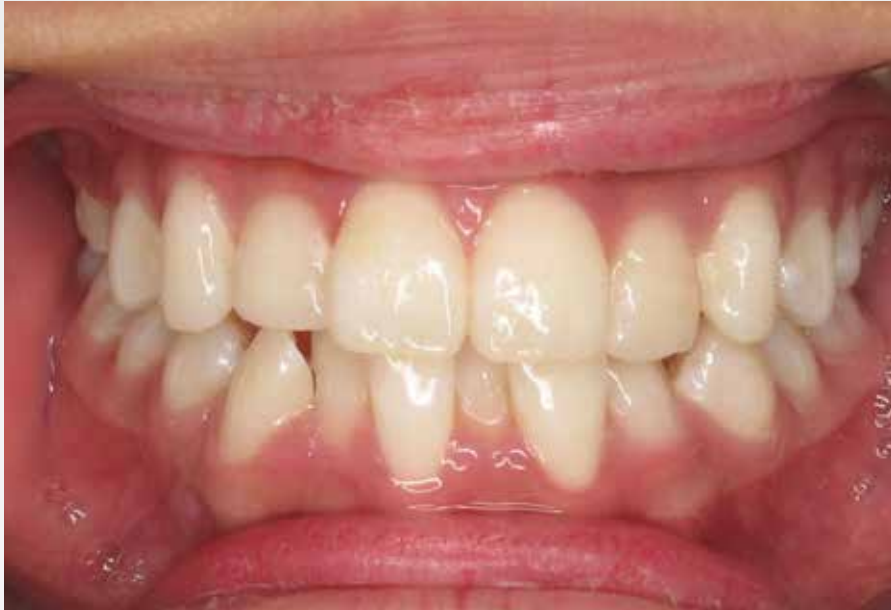

PROGRESS

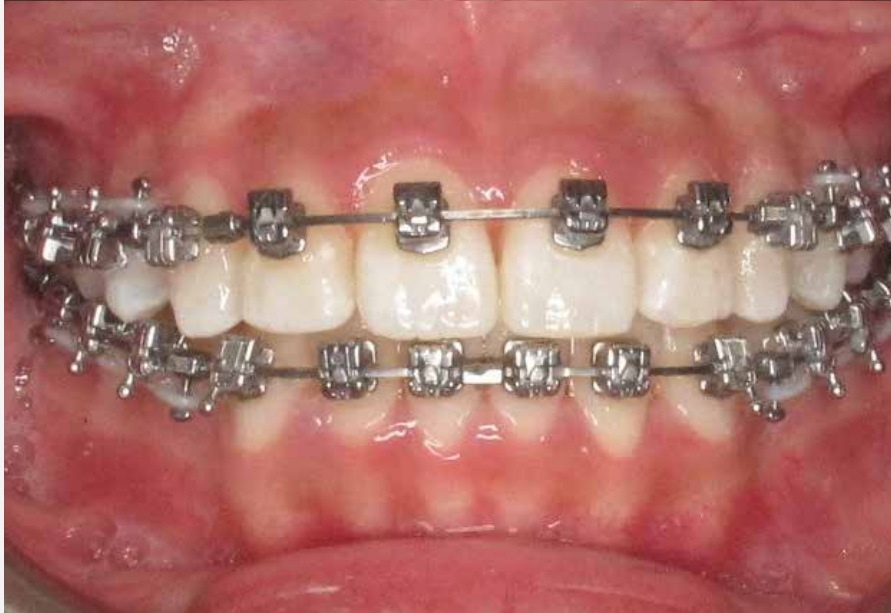

FINAL

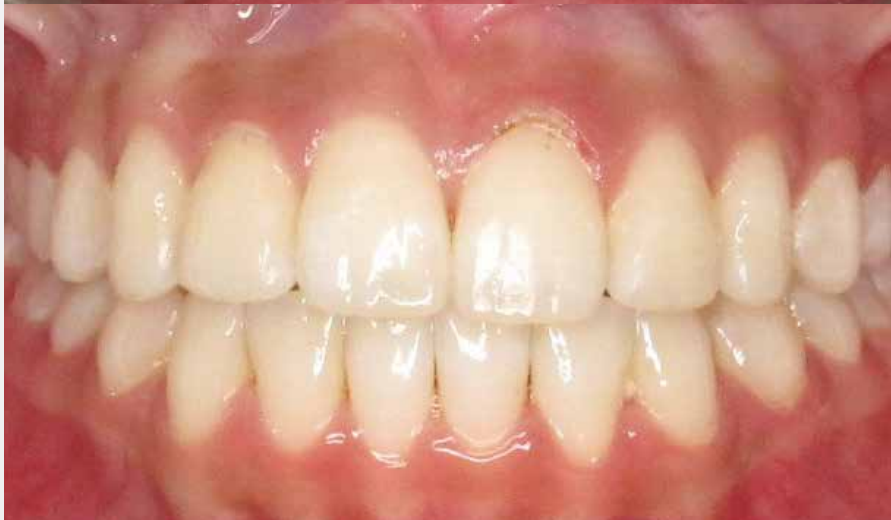INITIAL



PROGRESS



FINAL



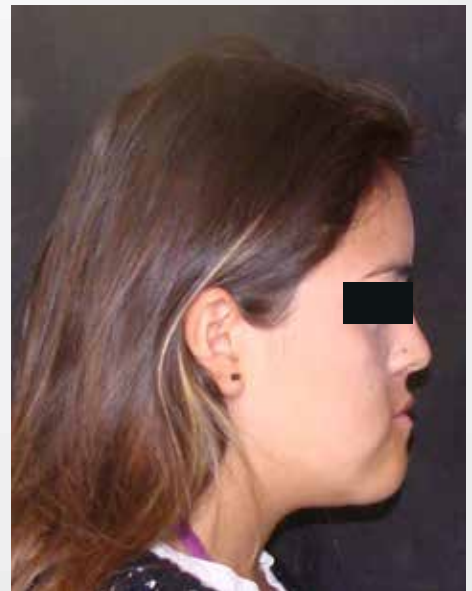
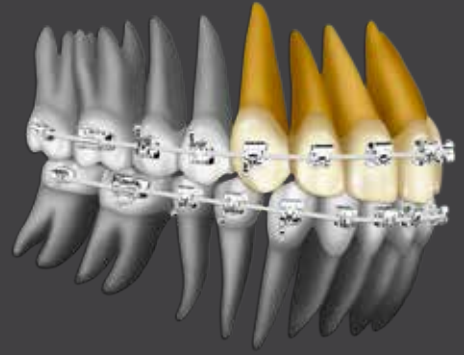
Note: Final midline is slightly off due to patient consistently sleeping on left side.



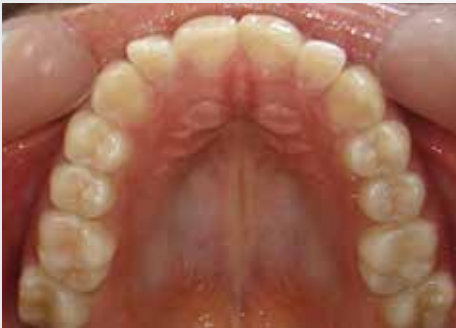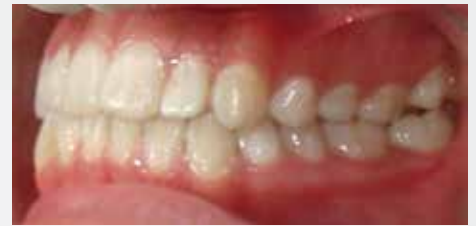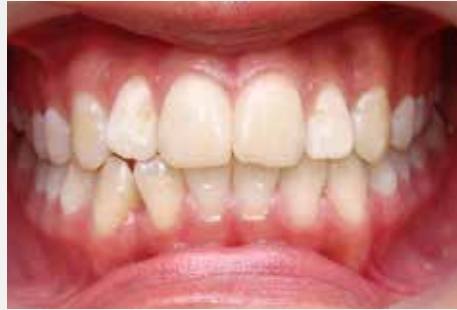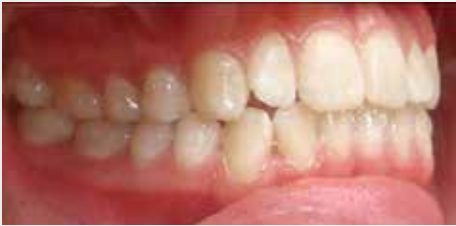Patient of
Dr. Tomas Castellanos

“Flipped & Flocked” Appliance

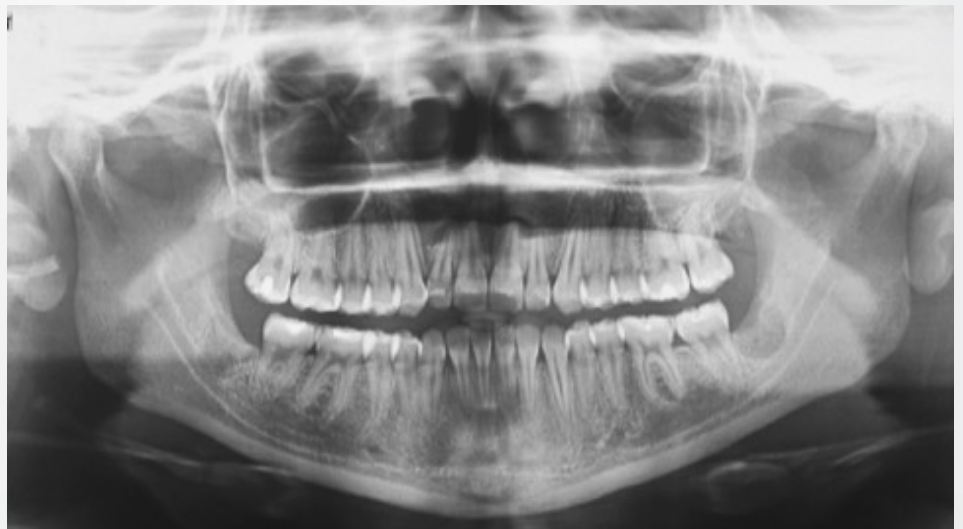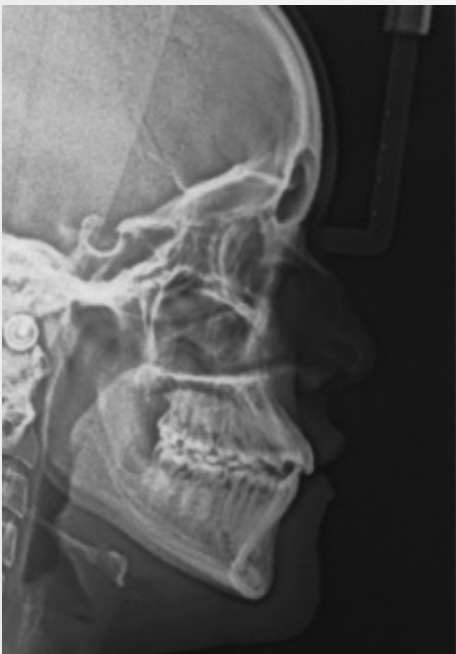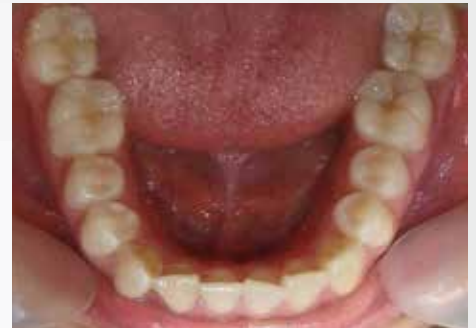*Class III Tendency
Proclination
Mild Crowding in Upper & Lower Arc
Flat Smile Arc*



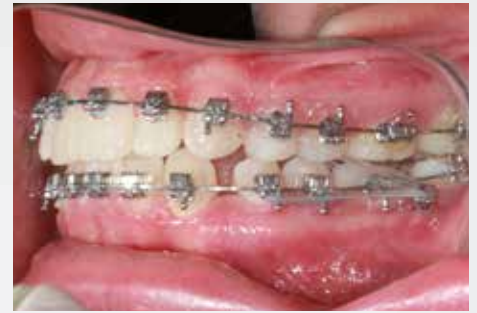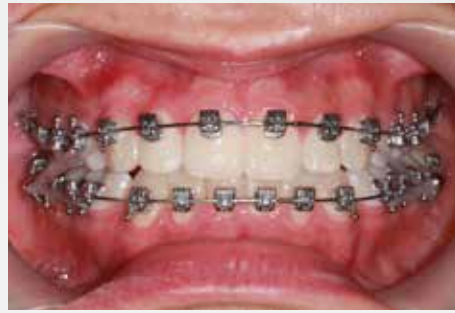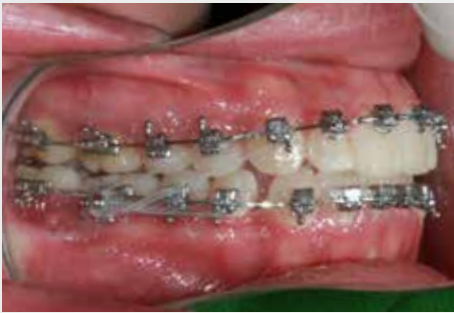Pre-Treatment Views



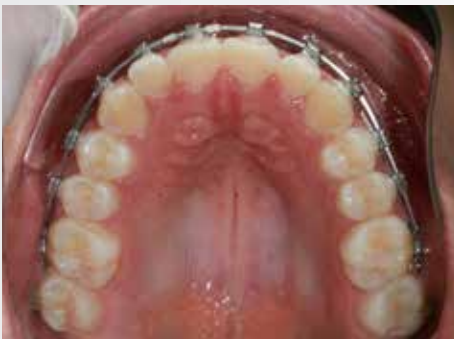Reconstruction and recontouring
 Stripping in lower and upper incisors
 H4 brackets -SAP protocol TOM &
 TOM positioning table



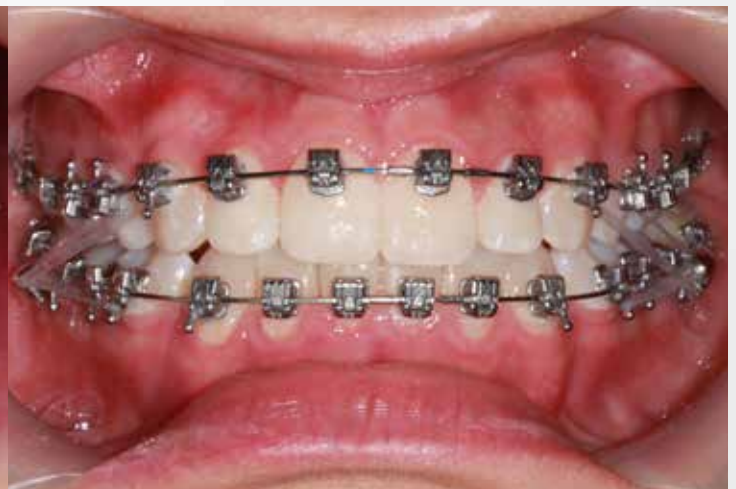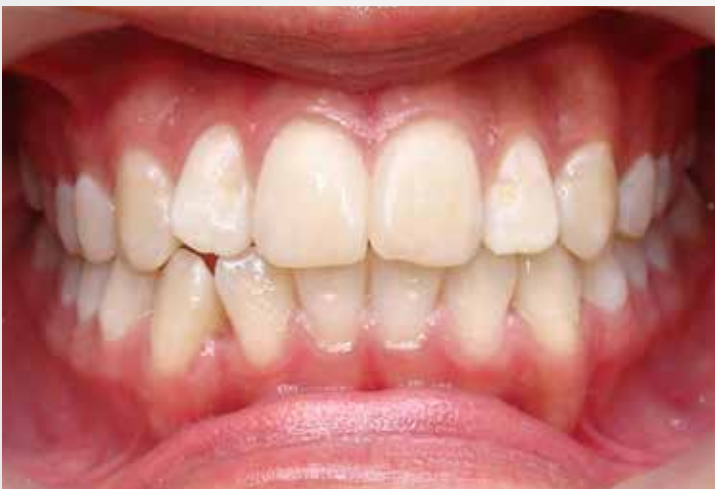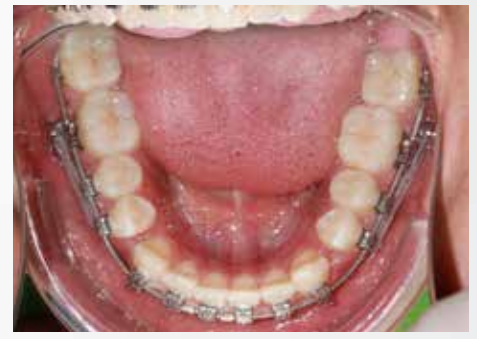Pre-Treatment Views

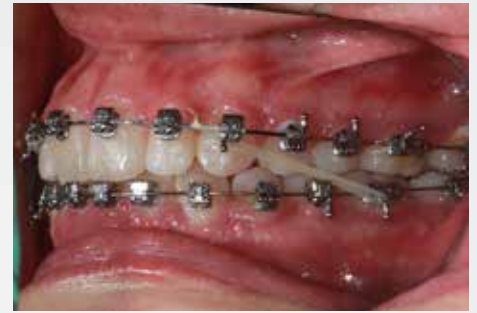
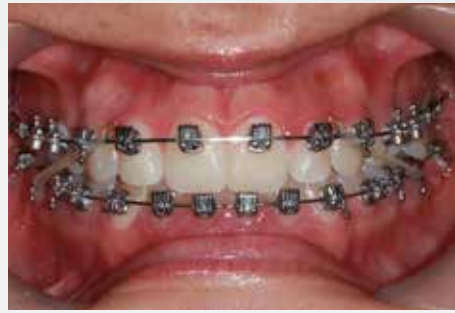
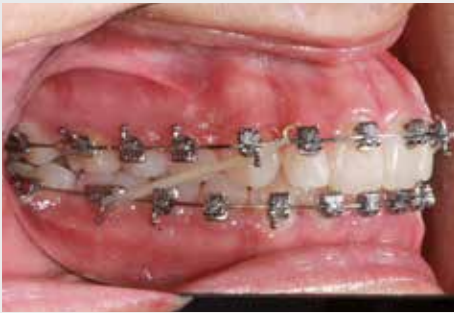In Treatment Views - 9 Months - 5 Appointments

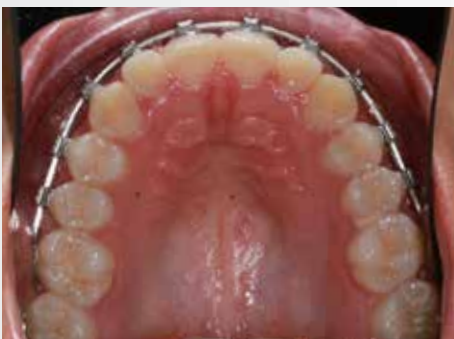

“Flipped & Flocked” Appliance
 (U3 to U3)
 Upper: .014 NiTi
 Lower: .014 NiTi
 2x12mm SS screw on buccal shelf
 CII E 2.5 oz. from U3 to screw
 Powerchain 2.5 oz. from L4 to screw

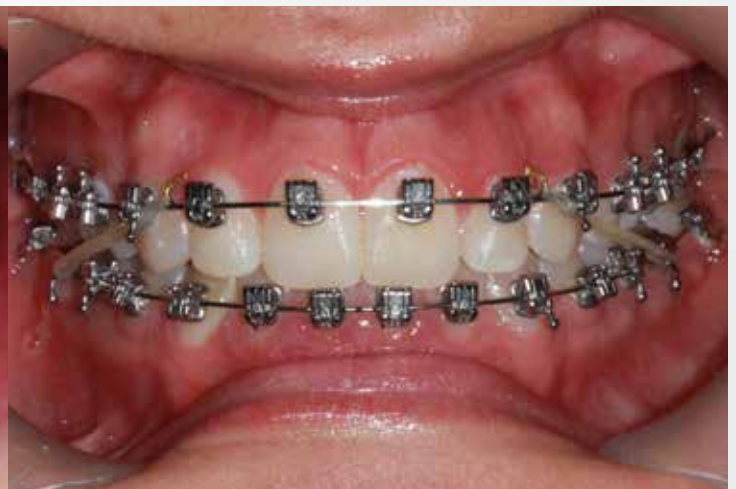
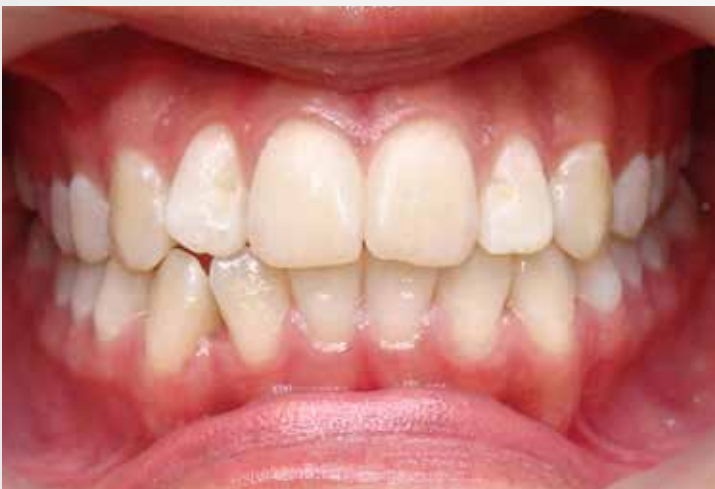
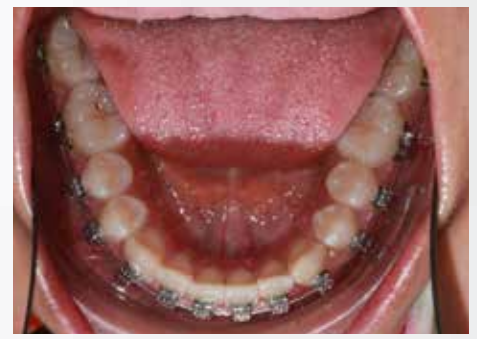

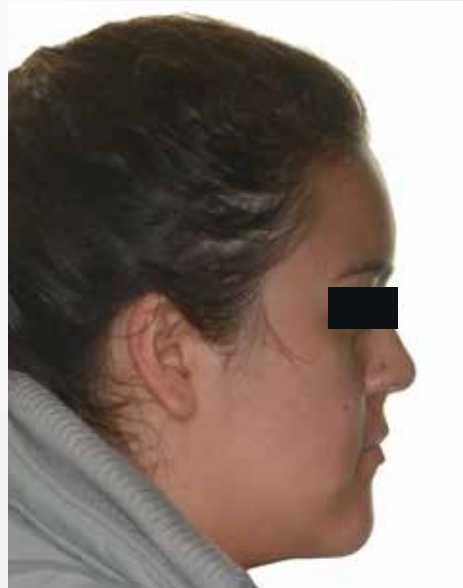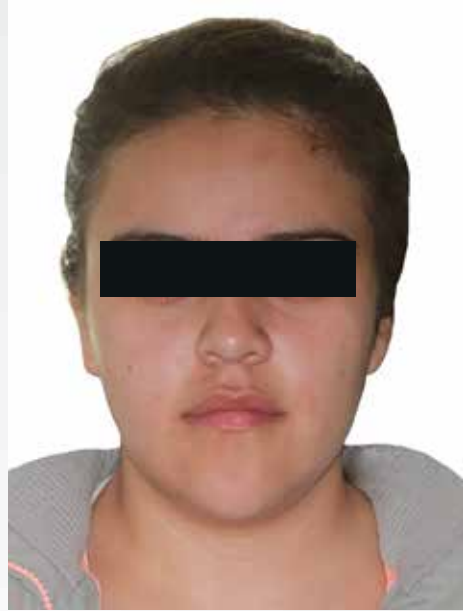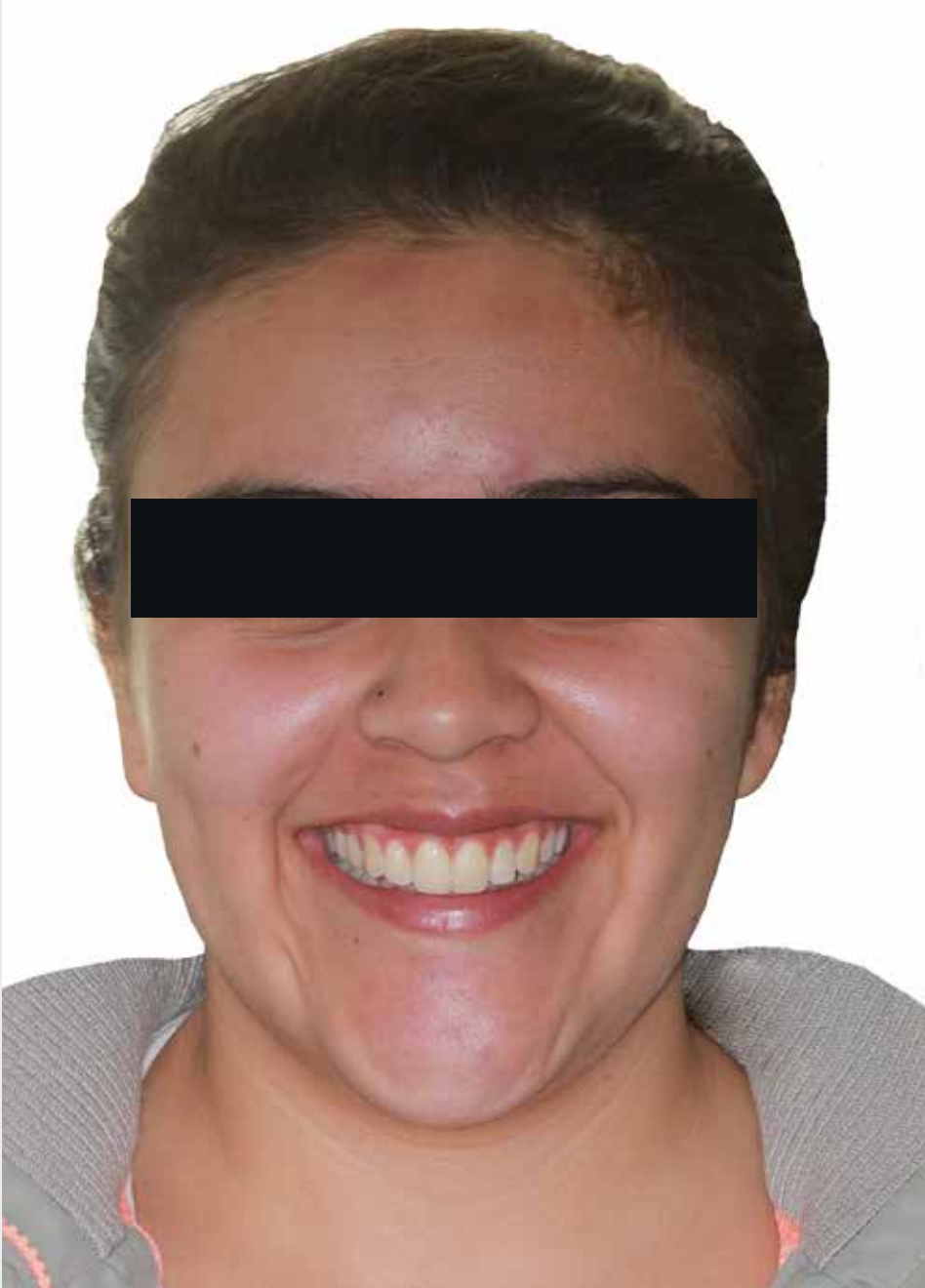In Treatment Views - 12 Months - 7 Appointments

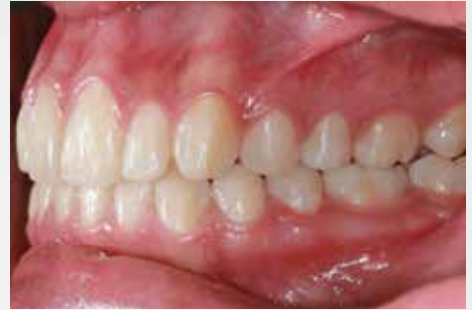
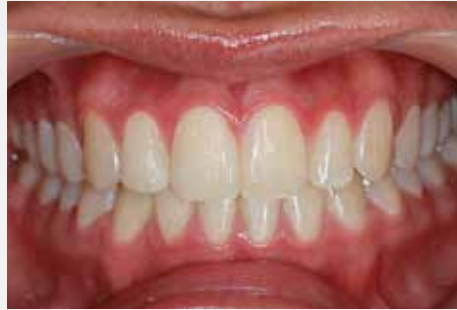
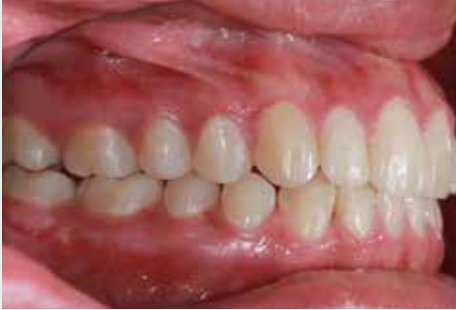U/L : .017 x .025 S.S.
2x12mm SS screw on buccal shelf
CII E 3.5 oz. from U3 to
the welding hooks

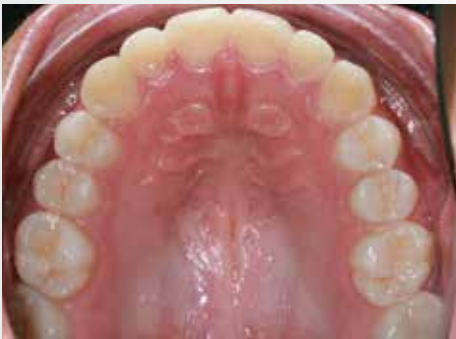



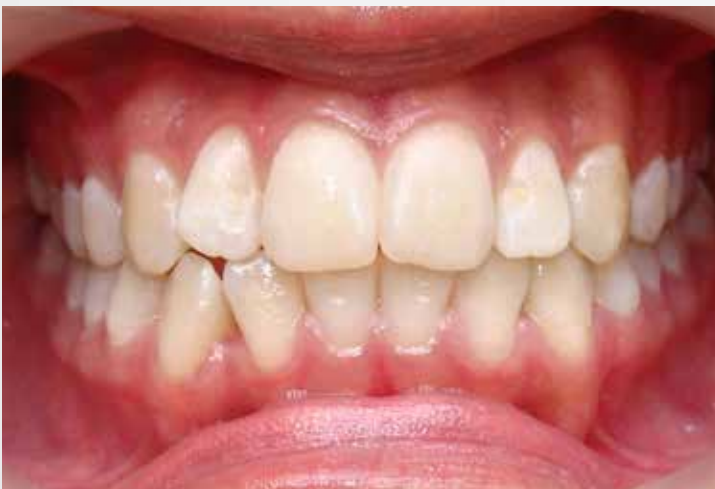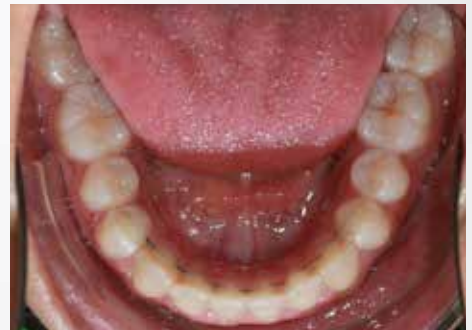Final Treatment - 14 Months - 9 Appointments



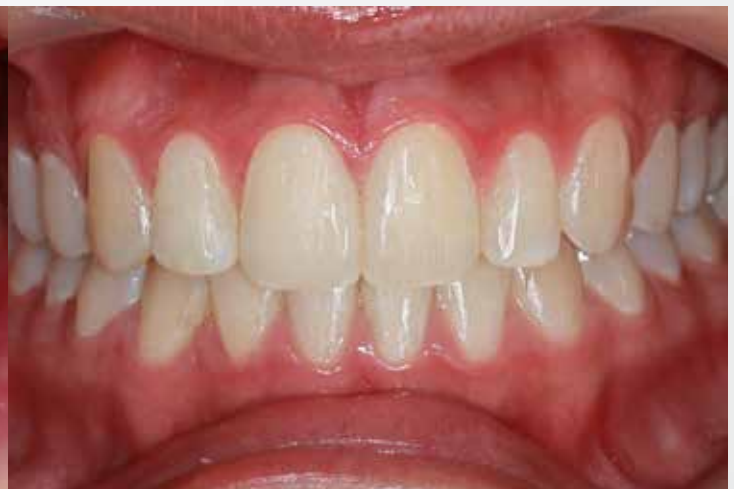One Month After Gingivoplasty and Final Recontouring - 15 Months - 10 Appointments



Result After:
Aesthetic and Altering Functional Occlusal Plane with Smile Arc Protection Concept

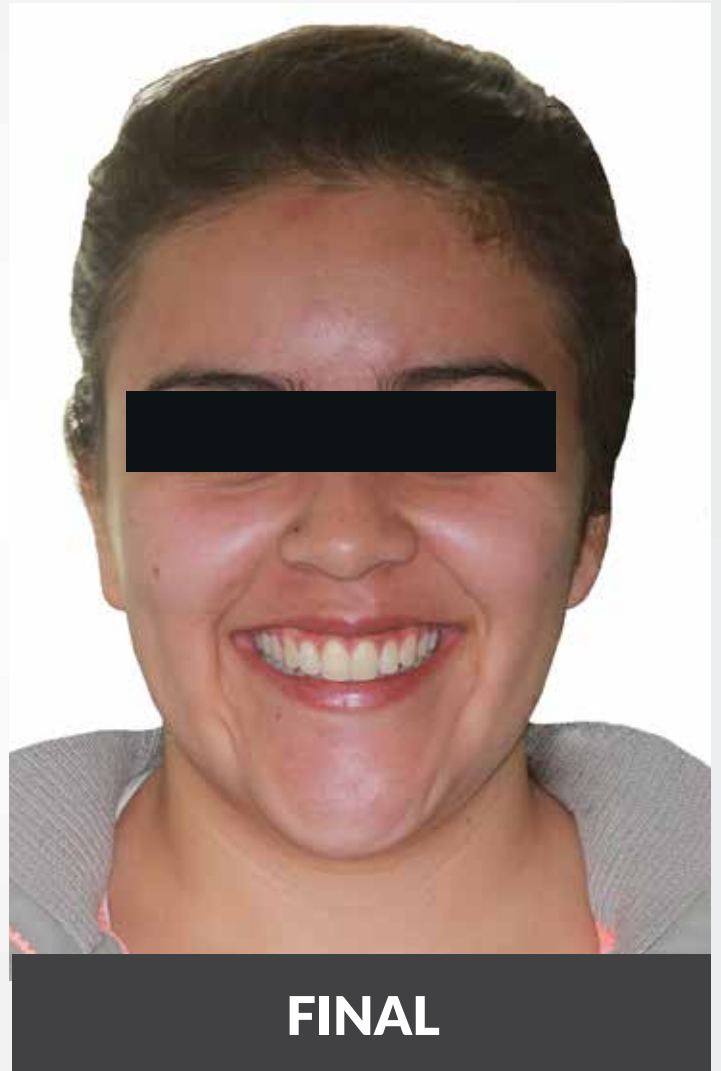

Before



After

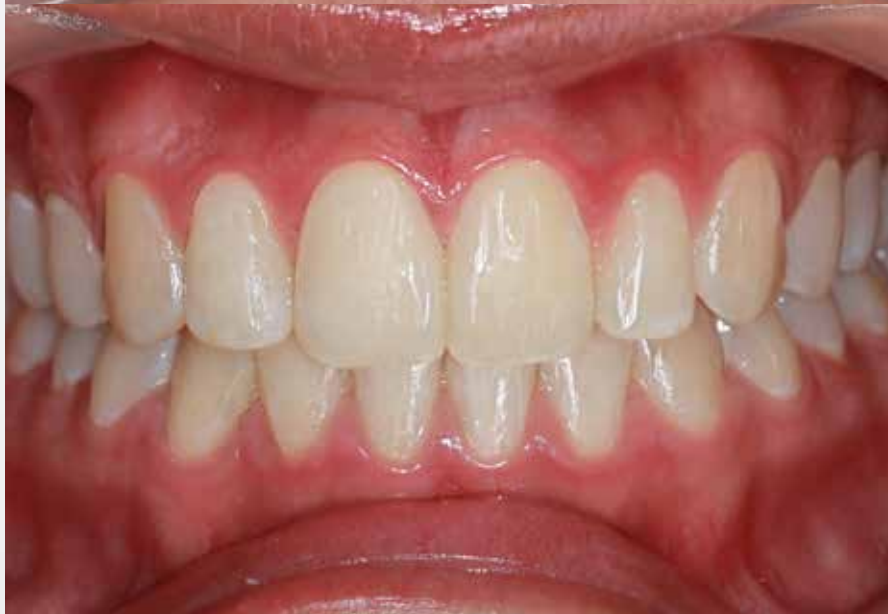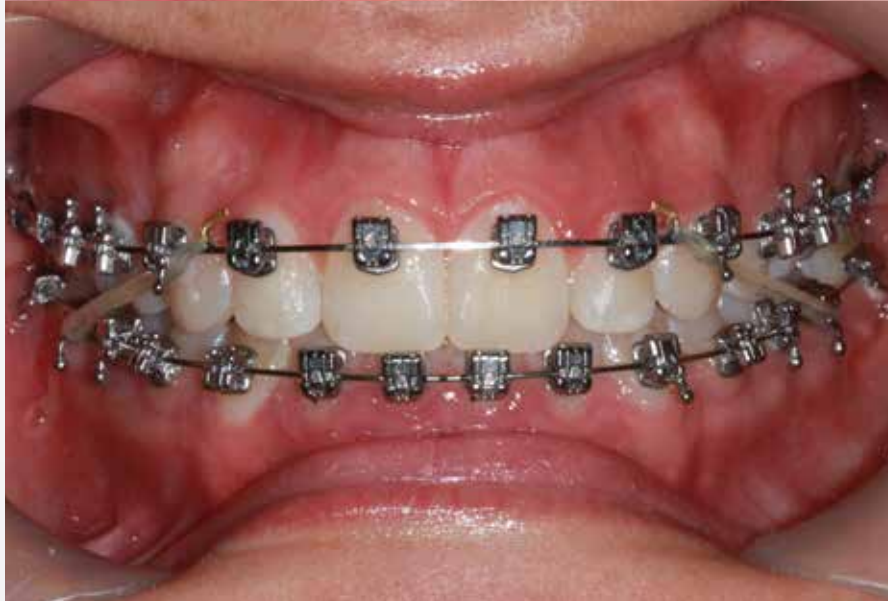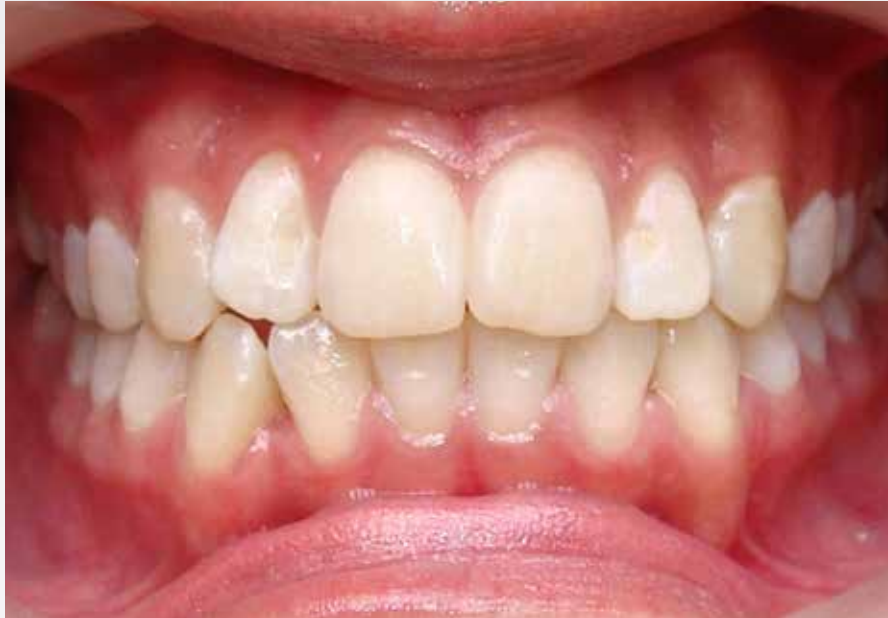© ORTHOEVOLVE 2015



INITIAL

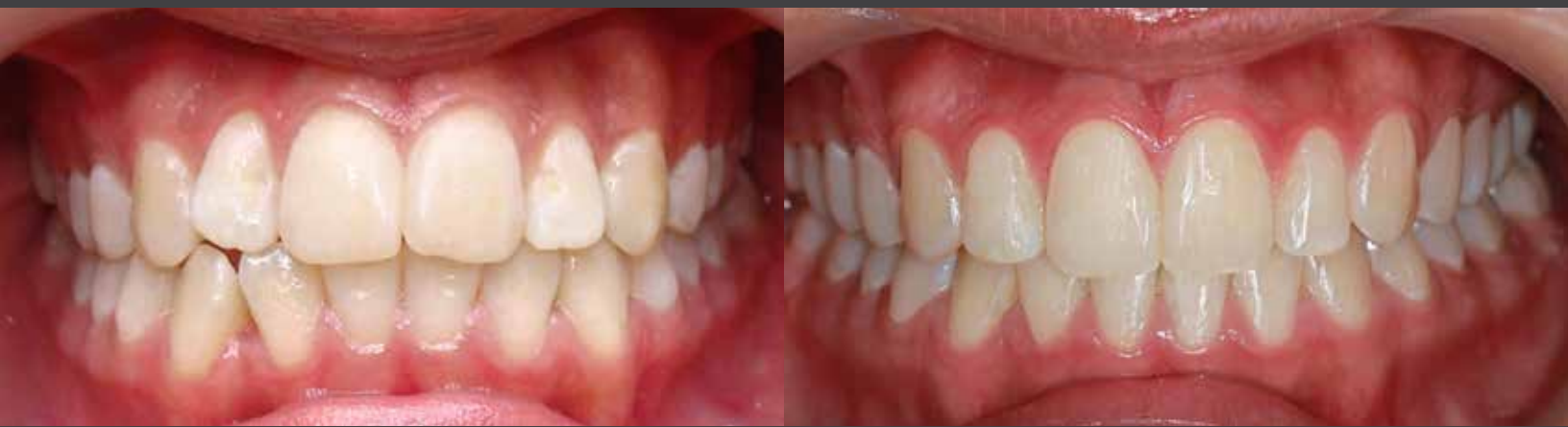PROGRESS

FINAL





CLINICAL BOOK



Ortho Classic, Inc.
1300 NE Alpha Dr.
McMinnville, OR 97128 USA

Follow Us On:



U.S. and Puerto Rico: 866.752.0065

Outside the U.S.: +1.503.472.8320

Fax: 866.752.0066

Email: sales@orthoclassic.com

Web: www.orthoclassic.com

©2016 All Rights Reserved

Ortho Classic, Inc.

REV. A - 01/21/16